

Minor Surgery Workshop



Zachary Moaveni

Plastic & Cranio-maxillofacial Surgeon

'Minor' Plastic Surgical Procedures

- 'Minor' in scope & complexity, **not** importance
- Usually skin cancers
- Usually under LA
- Usually out-patients

Today we'll aim to cover:

- Local anaesthetic technique
- Punch biopsy
- Choosing aesthetic incisions
- Reconstructive 'toolbox'
- Choosing the optimal reconstruction

Local Anaesthesia

- My recipe:
 - 5ml lignocaine 2%
 - 5ml marcaine 0.5%
 - 0.1ml adrenaline 1:1000

Gives 1:100,000 adrenaline, rapid onset and prolonged duration

Where can you use adrenaline?

- Everywhere!
- But use rubber band instead on fingers

Tips & Tricks

- Keep talking (and apologising!) to patient as you inject slowly
- Use nerve blocks where possible
- Use field blocks
- Wait a sufficient amount of time

Punch Biopsy



Zachary Moaveni

Plastic & Cranio-maxillofacial Surgeon

Punch Biopsy

- Primary technique for obtaining full-thickness specimens for histological diagnosis.
- It is **ONLY** useful if it is representative of the lesion.
- Always trust your instincts!

When Not to ...

- Punch biopsy is not recommended for pigmented lesions

Technique

- Inform patient and obtain consent
- Mark the most abnormal / thickest area of the lesion. For ulcers, include an edge with normal skin.
- Prep with alcohol swab and infiltrate LA

- Sterile gloves, minimal touch technique
- Stabilize skin and hold punch vertically
- Use steady downward force and twirling motion
- Stop when you reach subcutaneous fat
- Use sterile needle to lift specimen (avoids crush) and cut with scissors
- Steristrips or suture

Choosing Aesthetic Incisions



Zachary Moaveni

Plastic & Cranio-maxillofacial Surgeon

Resting Skin Tension Lines

- RSTLs give the most aesthetic scars
- Perpendicular to muscle contraction lines
- Often coincide with wrinkles

Tips

- Longer scars can be better scars if tension is minimized.
- On upper trunk, make scars vertical in the midline and more oblique as you move laterally.
- If unsure of RSTL, use the 'circle to ellipse test'.

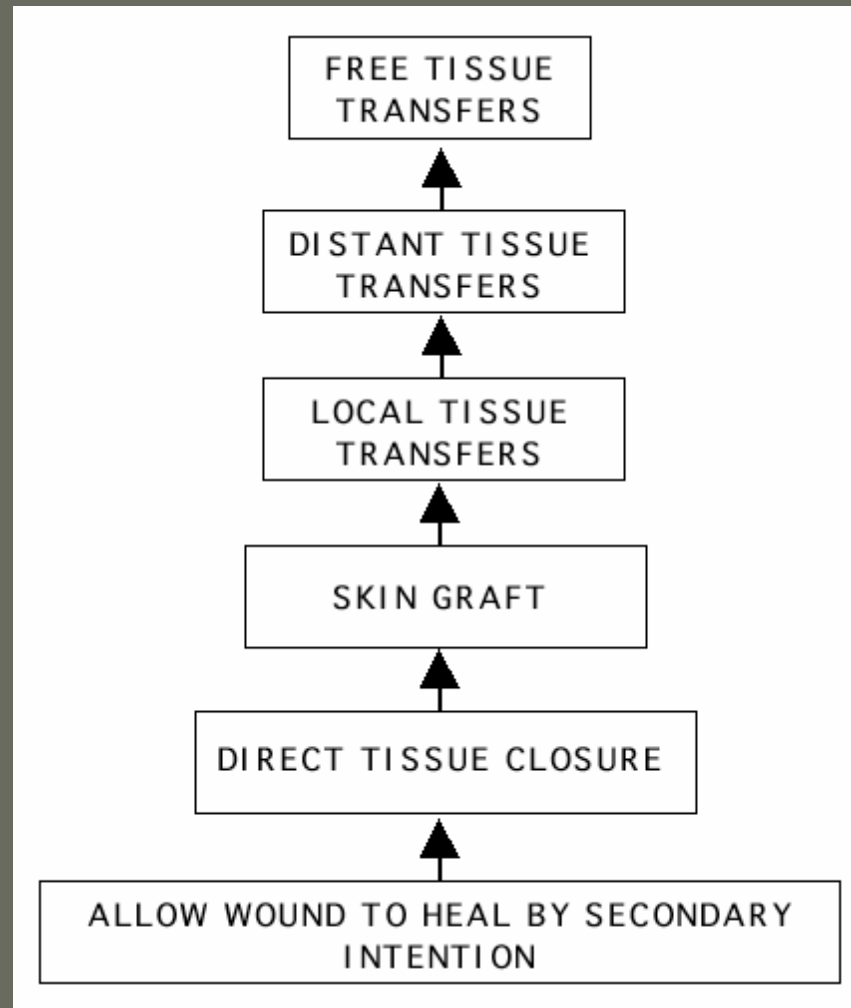
Reconstructive 'Toolbox'



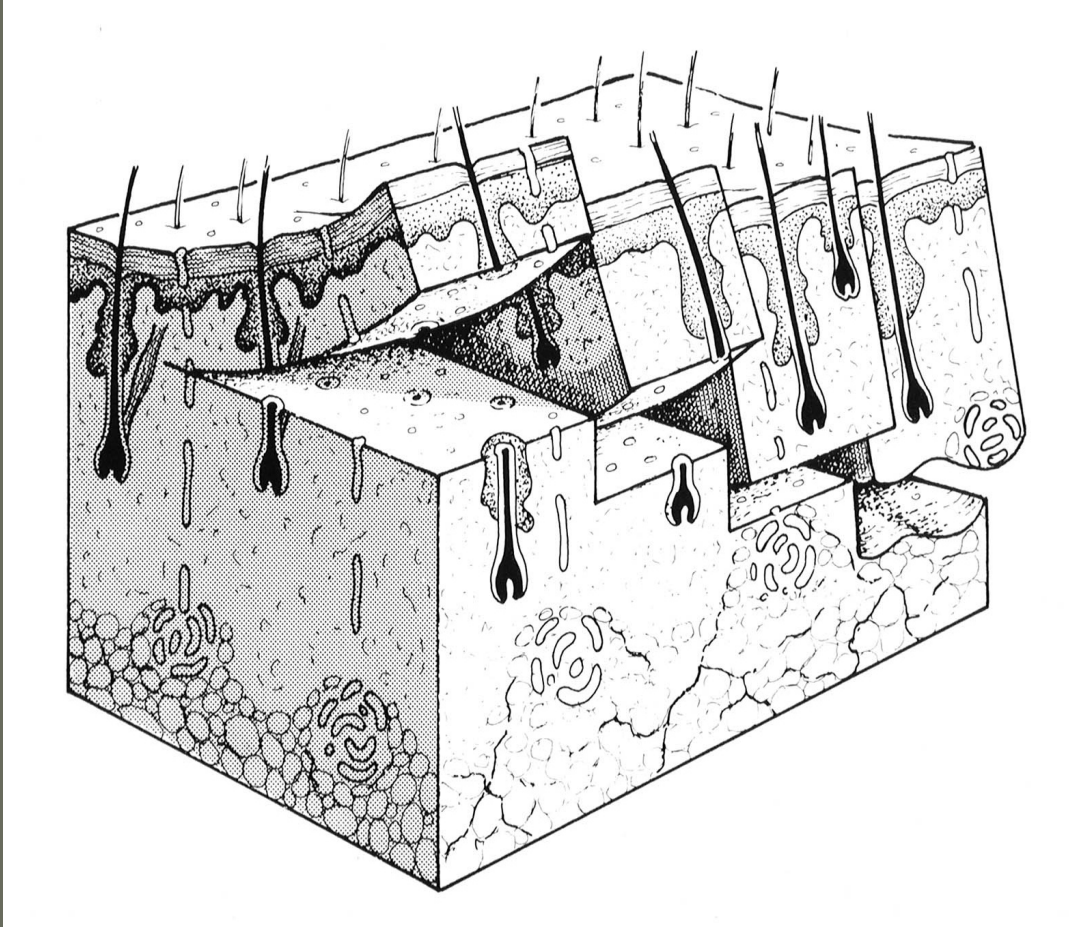
Zachary Moaveni

Plastic & Cranio-maxillofacial Surgeon

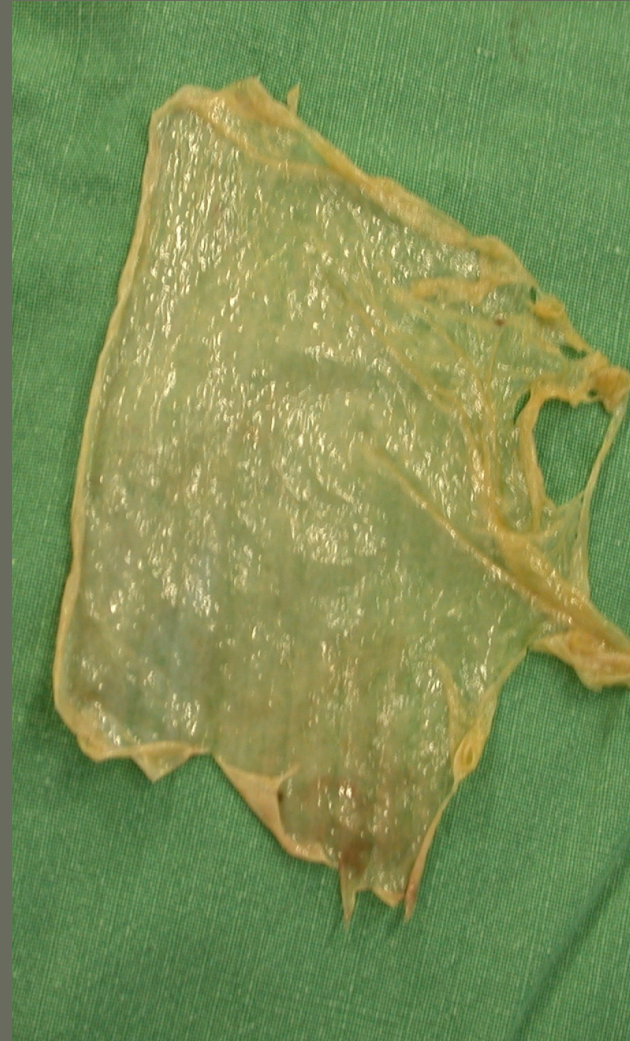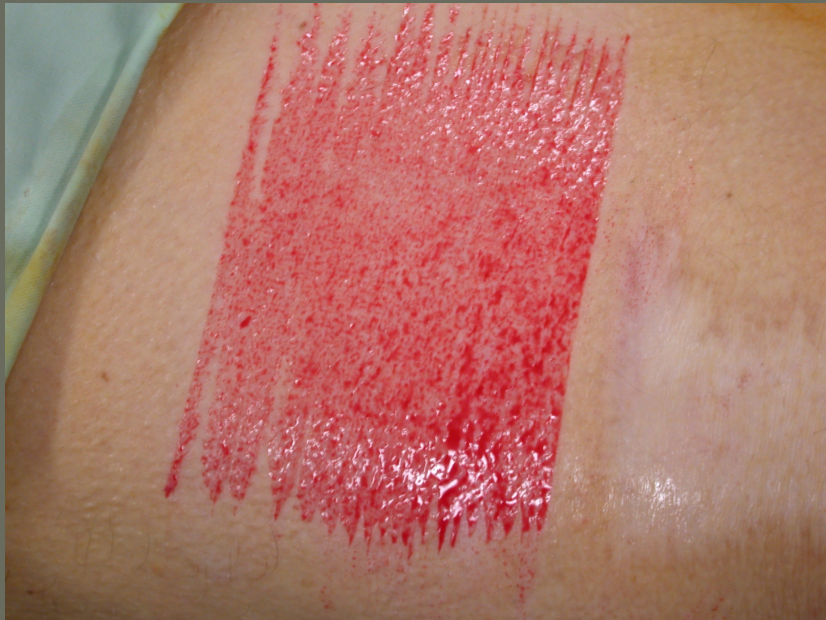The 'Reconstructive Ladder' Concept

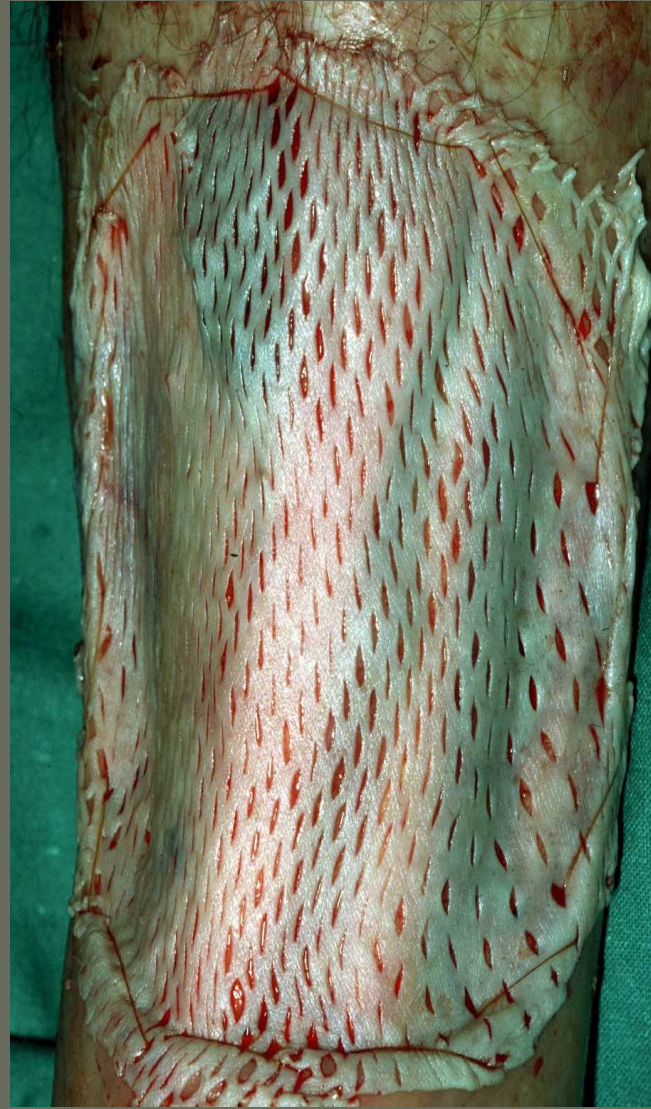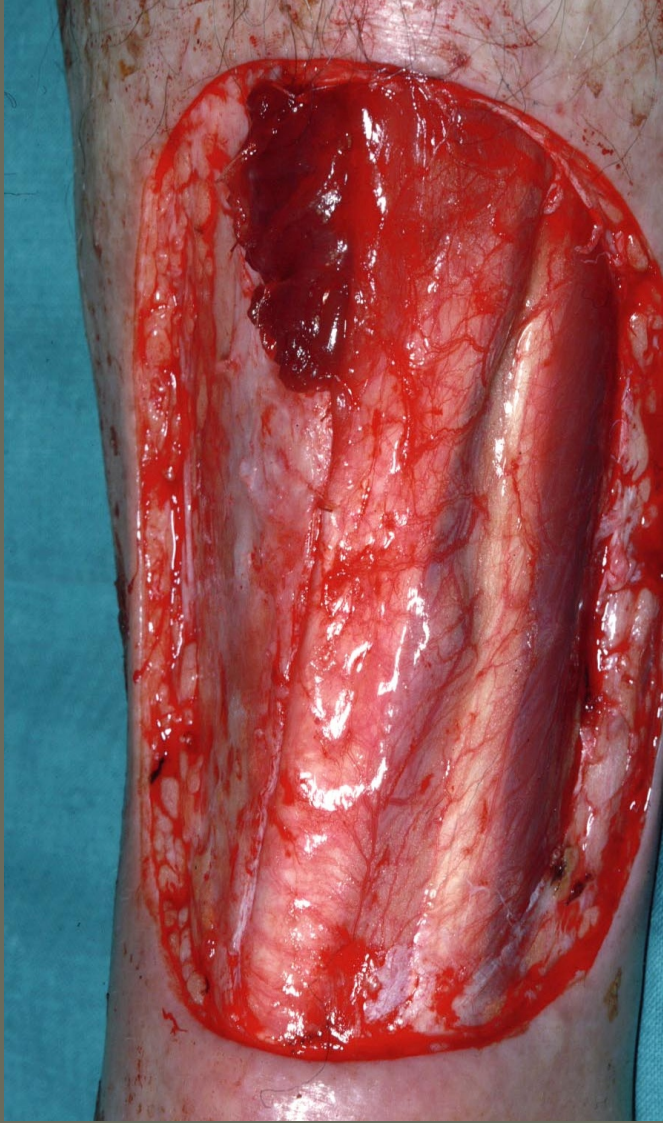


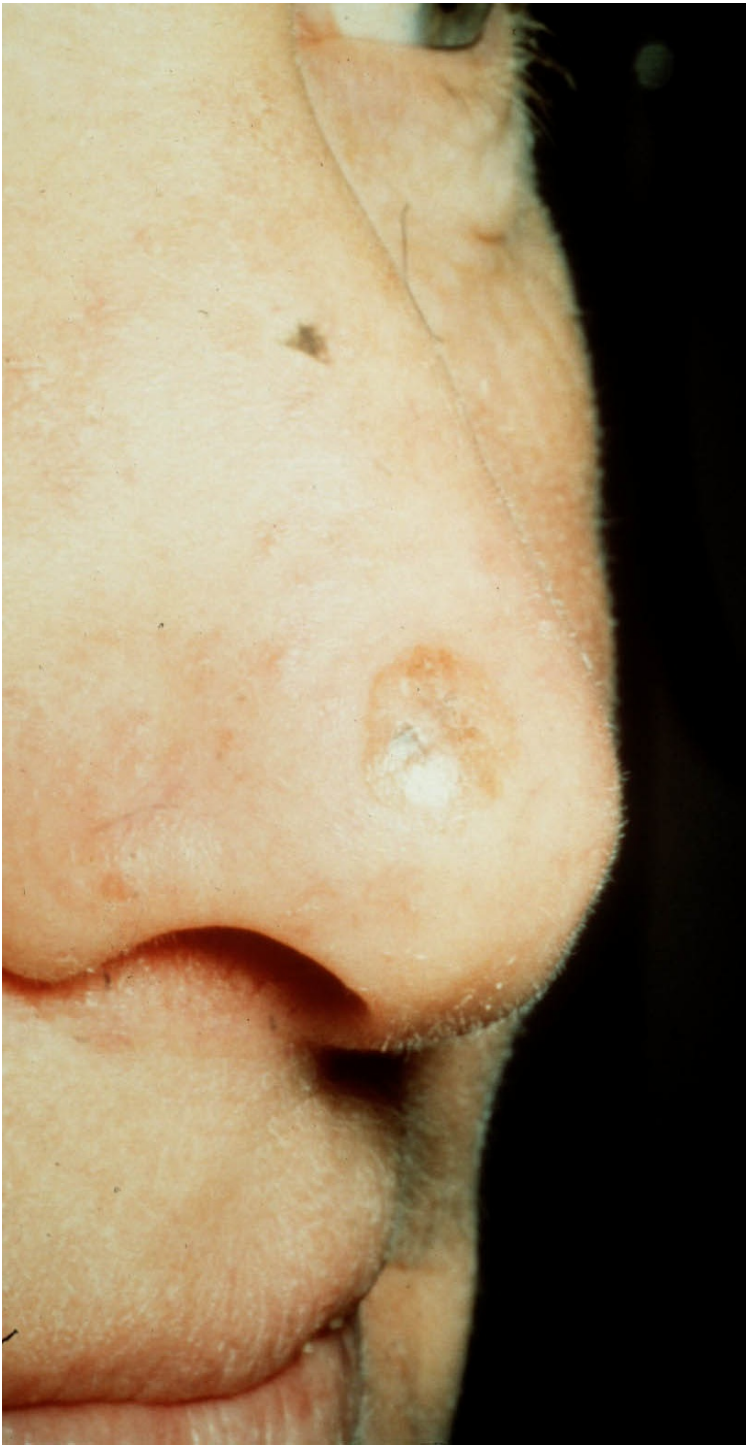Skin Grafts



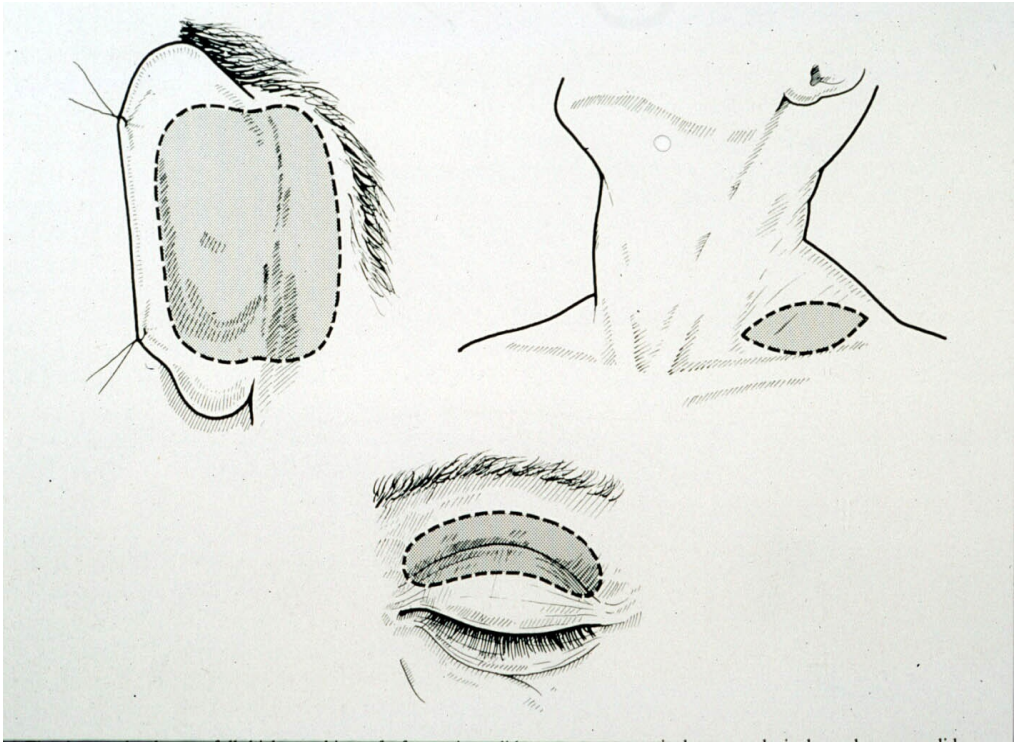
Partial Thickness Skin Grafts







Full Thickness Skin Graft

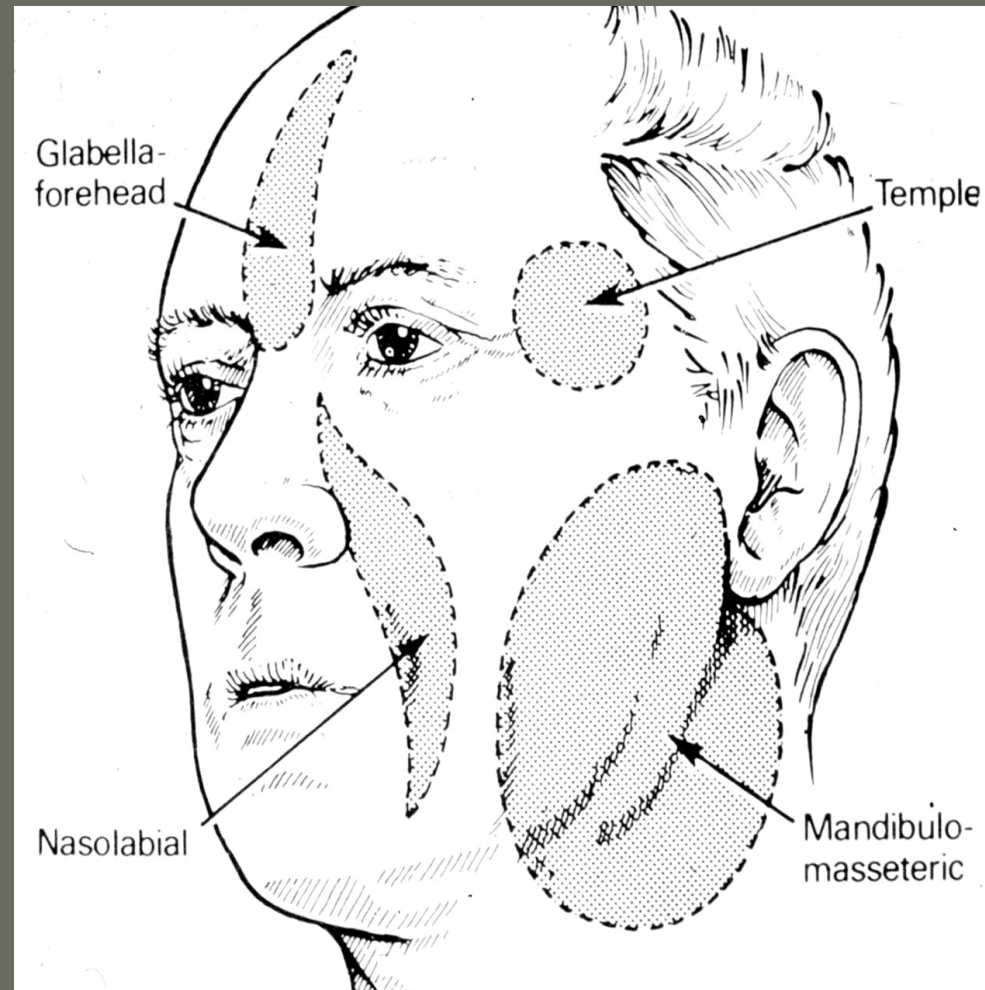


Local Flaps

Consider

- Adjacent areas of spare
- Means of transfer
- Single stage if possible

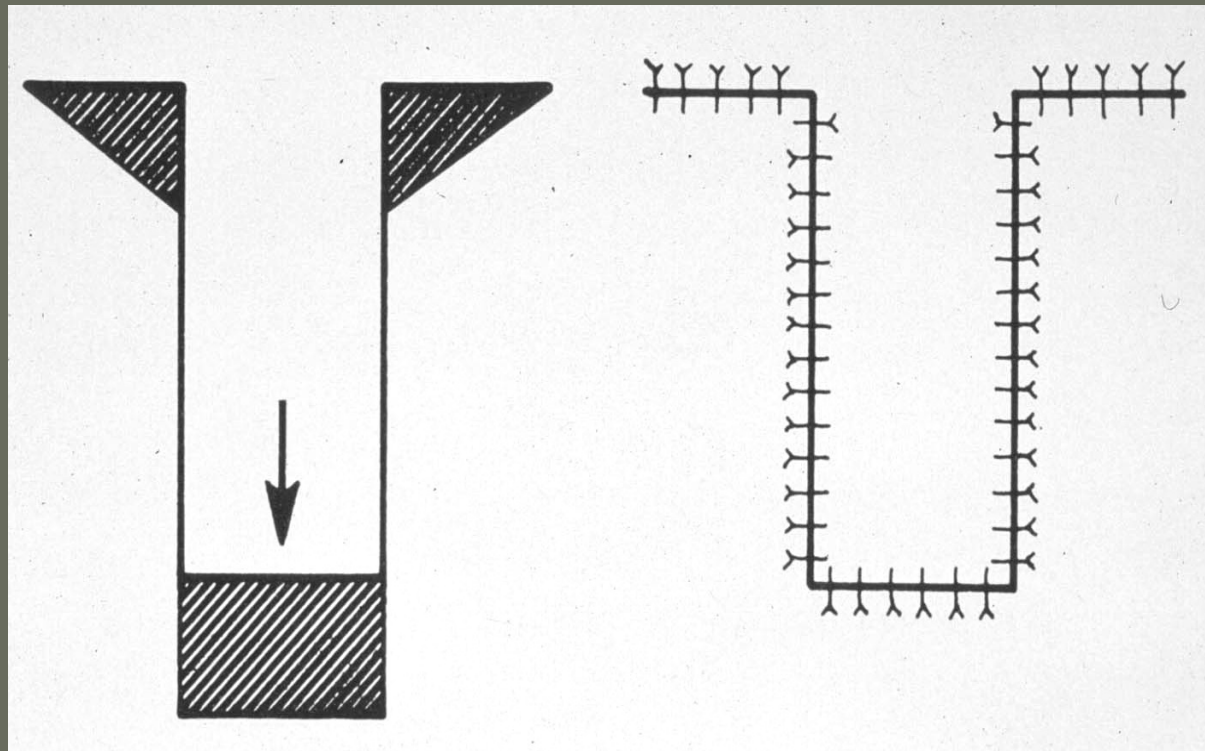
Areas of Spares



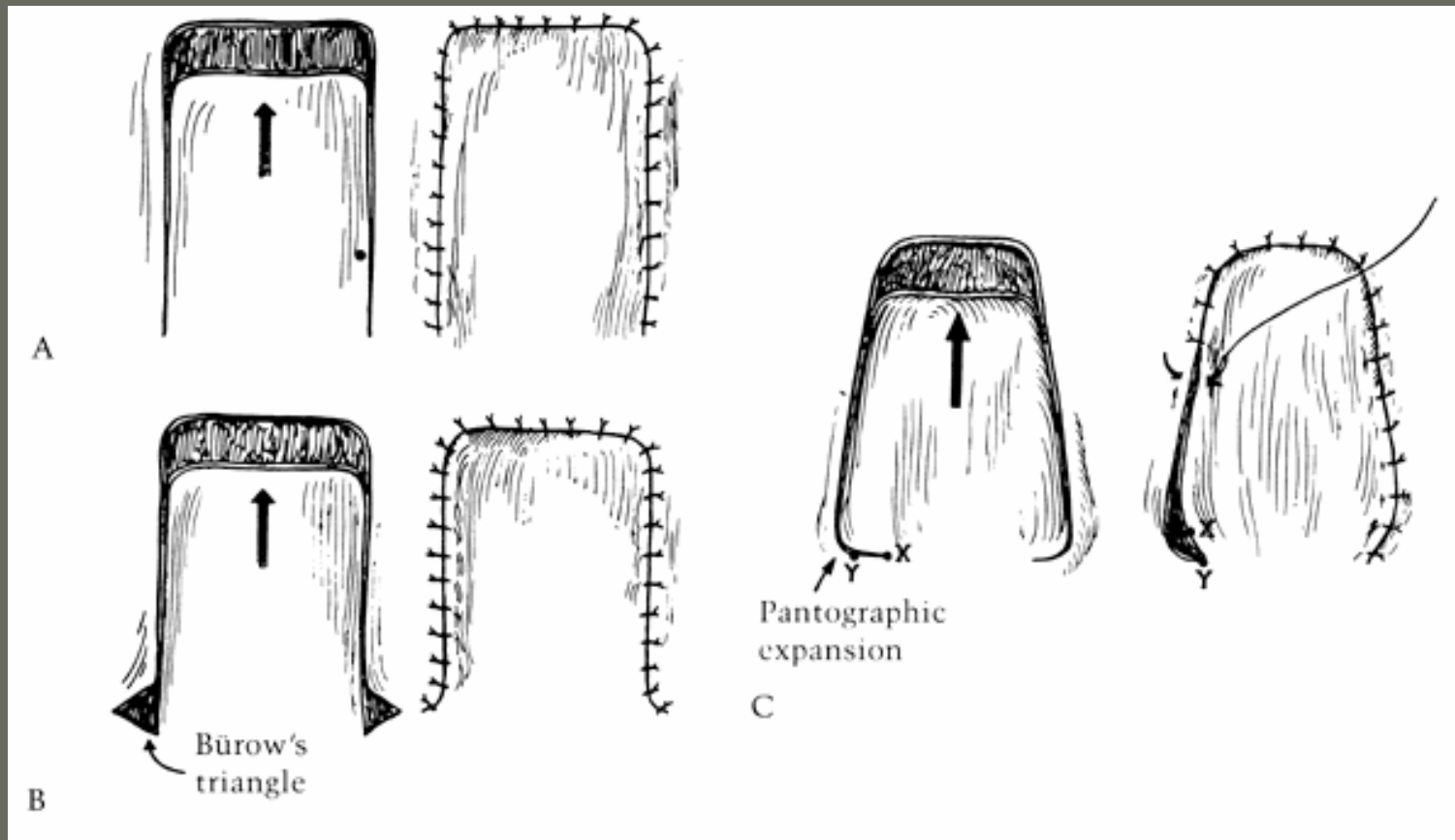
Local Flaps

- Advancement flaps
- Flaps rotating about a pivot point
 - rotation
 - transposition
 - interpolation

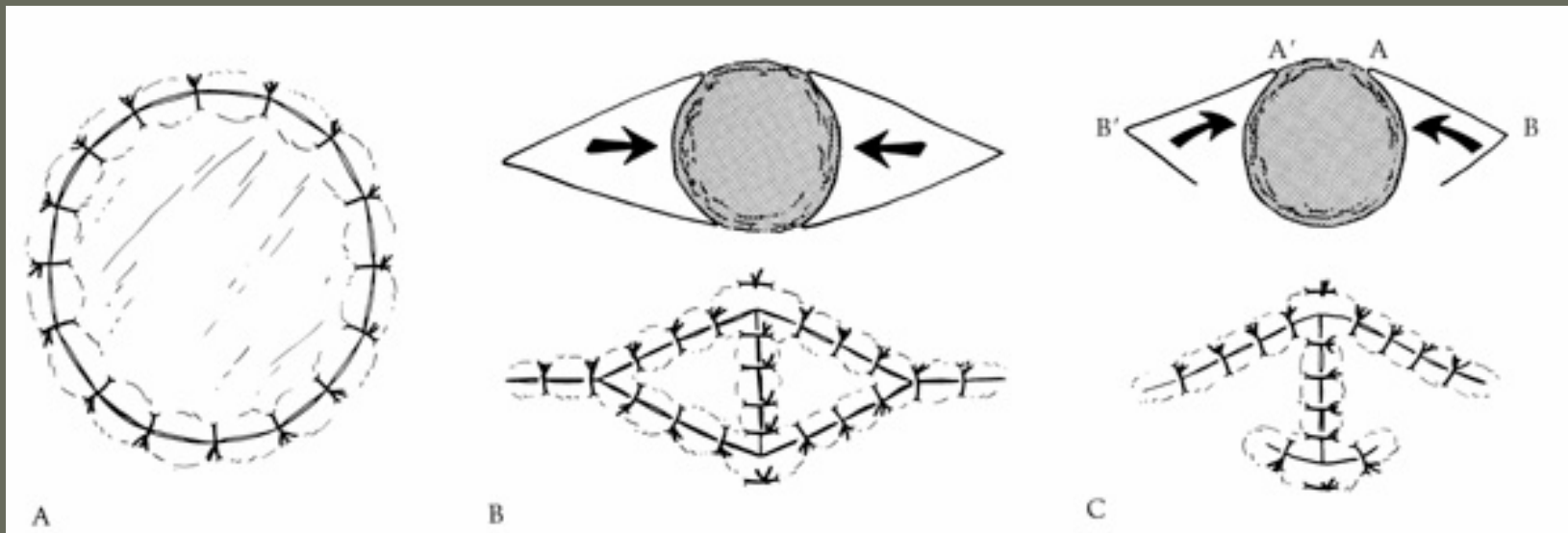
Advancement Flap



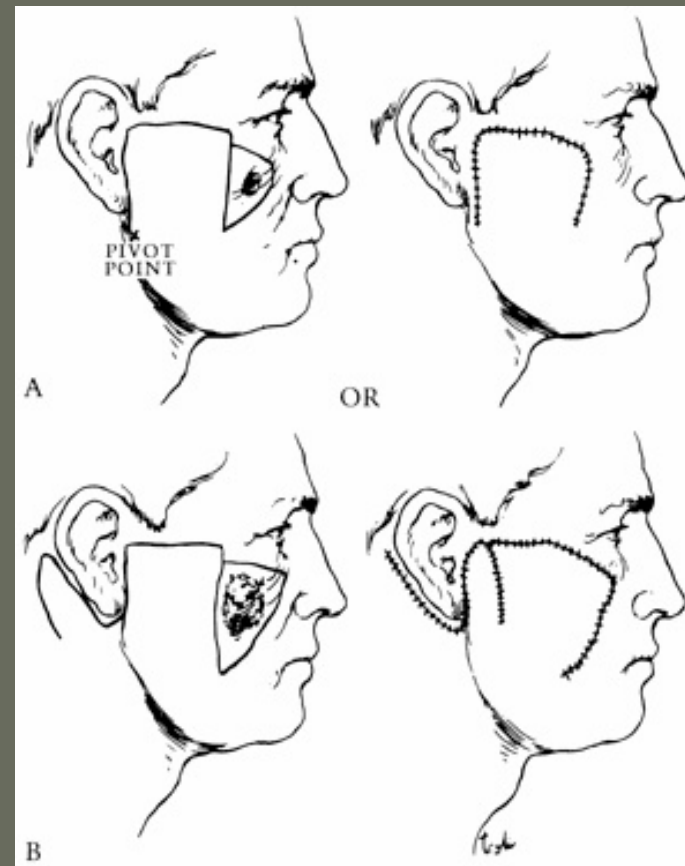
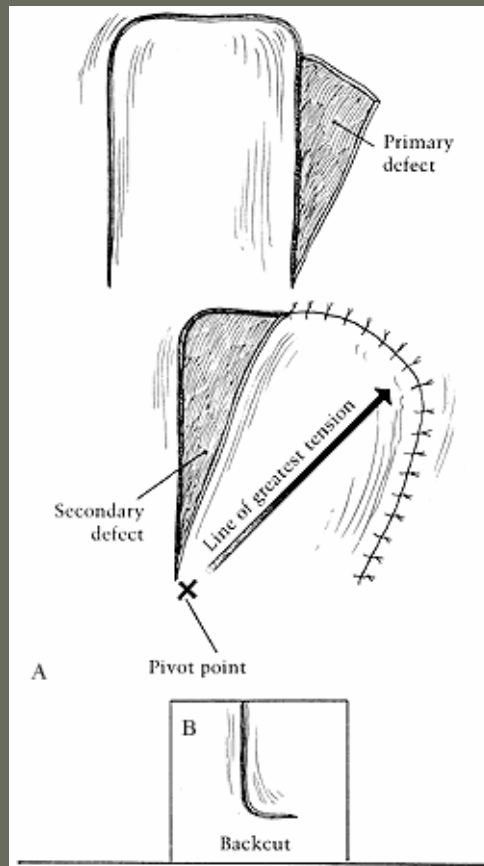
Advancement Flaps



Examples of Closures



Transposition Flaps



How to Approach a Reconstructive Problem?



Zachary Moaveni
Plastic & Cranio-maxillofacial Surgeon

Keys to success

- © Atraumatic, sterile technique
- © Appropriate sutures
- © Minimize tension
- © Wound support
- © Wound cover
- © Suture removal

Post suture removal care

©Wound support

©Massage

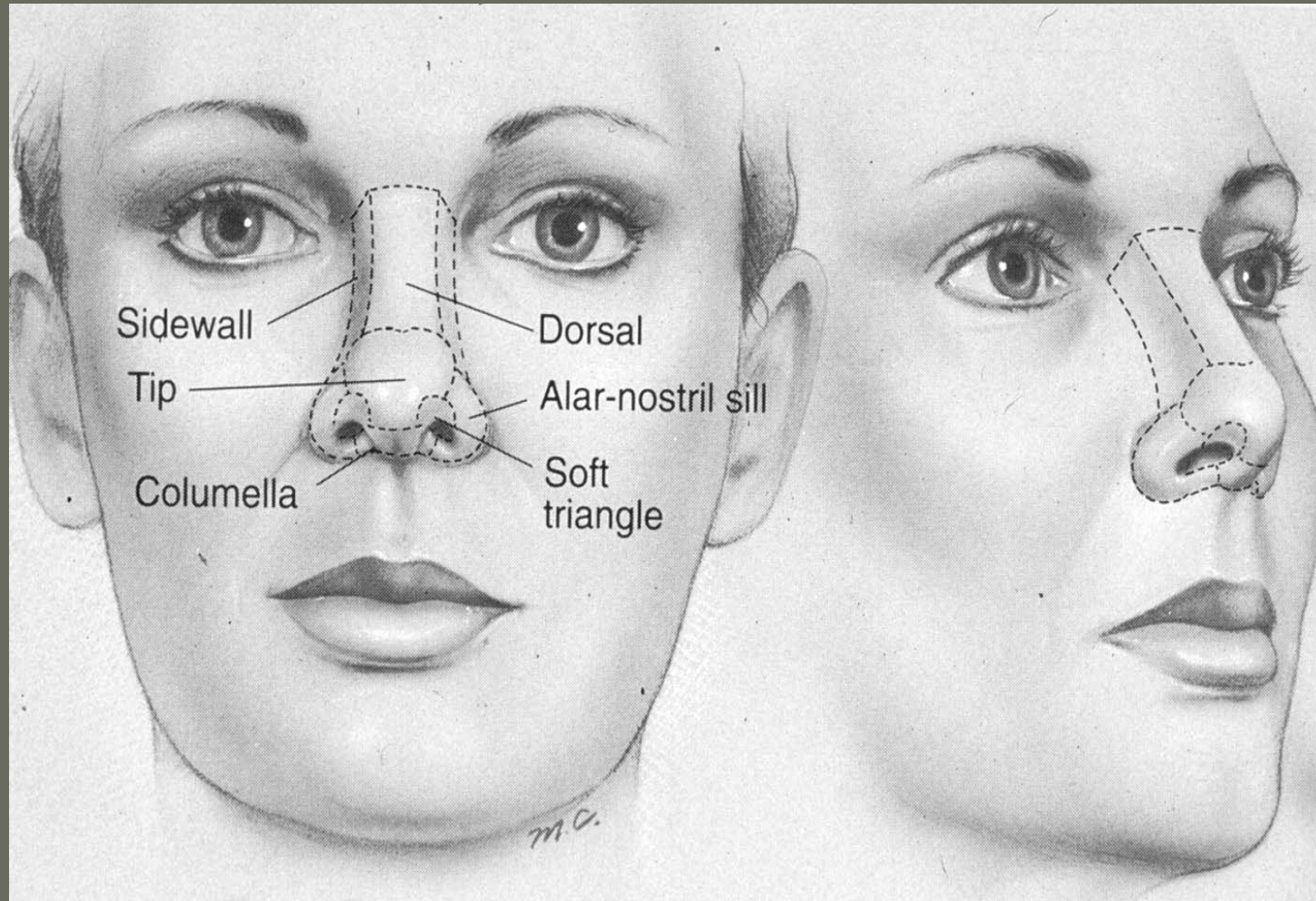
©Creams

©Sun protection

Reconstructive Principles

- Define the problem
- Replace like tissue with like tissue
- Always have a life boat (plan B)
- Only living tissue heals
- Respect cosmetic units/sub-units

Cosmetic Units and Sub-units



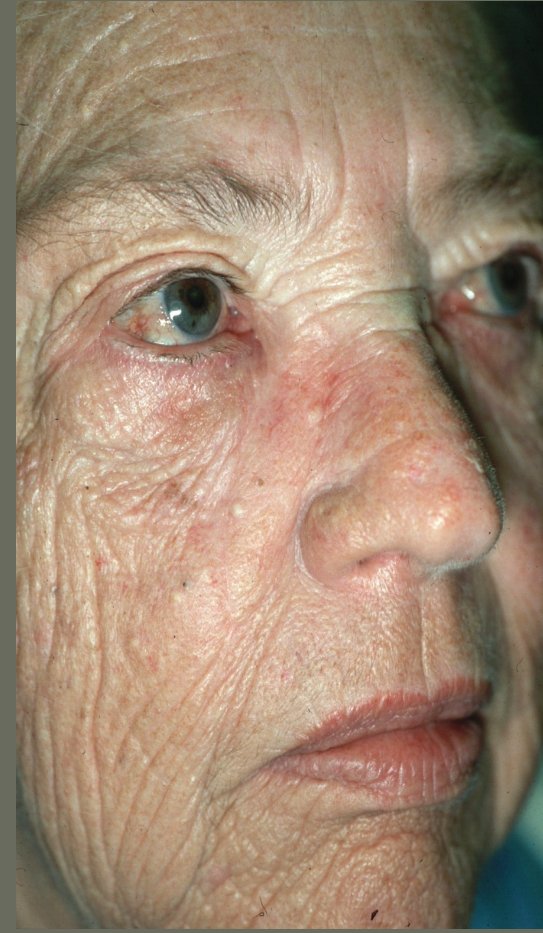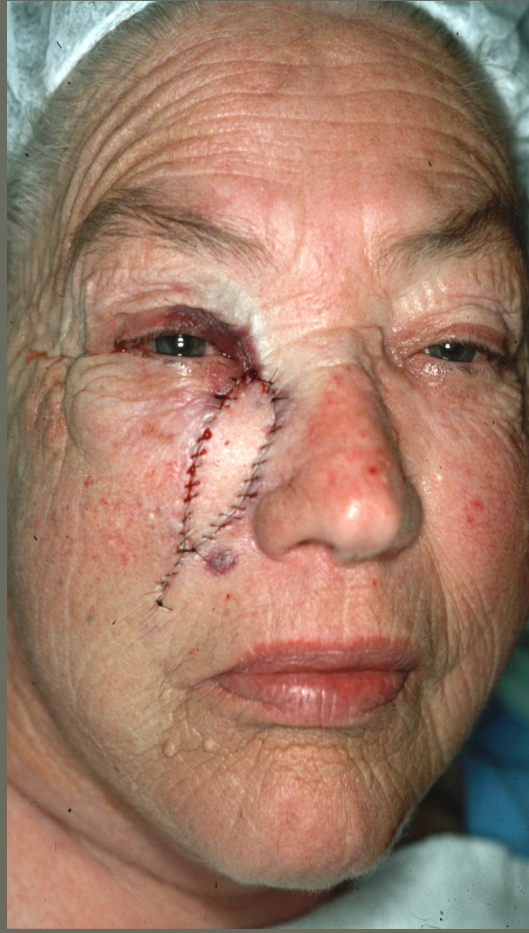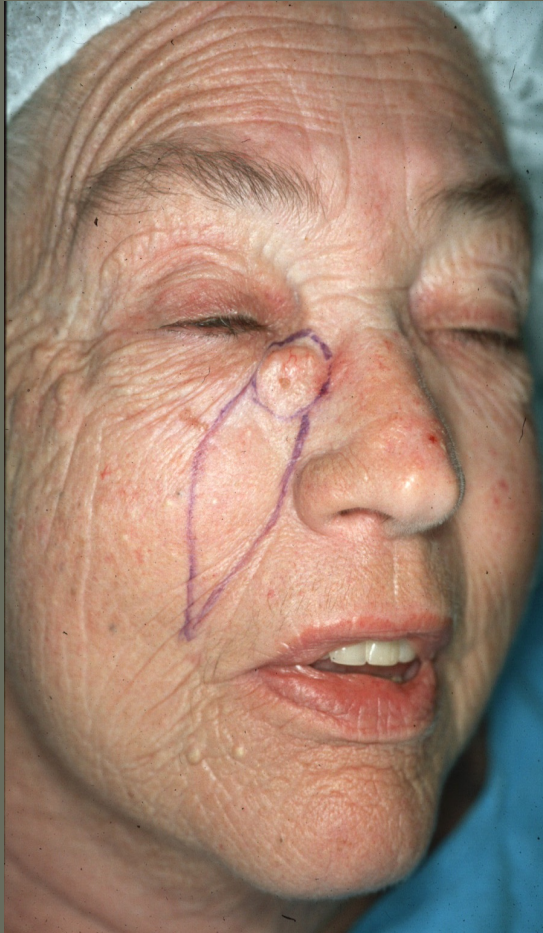Reconstructive Principles

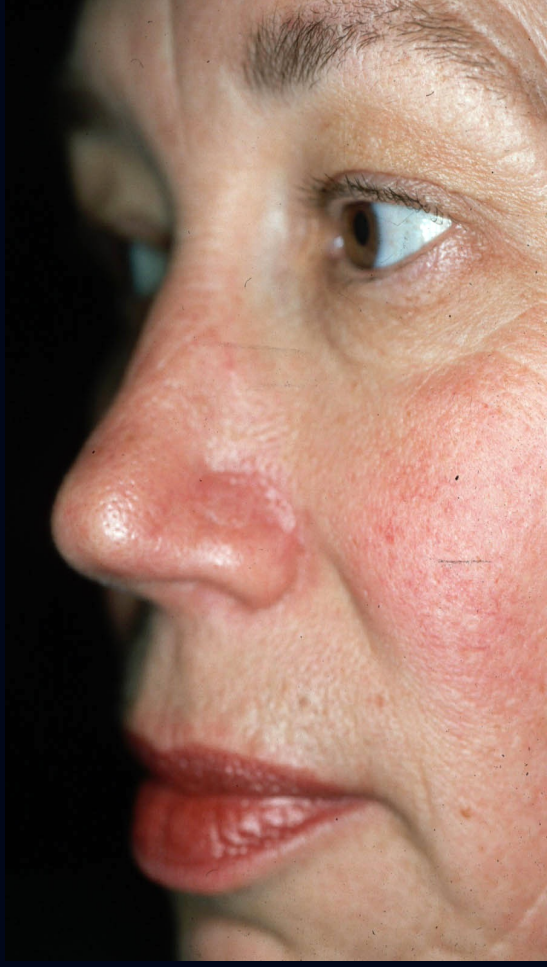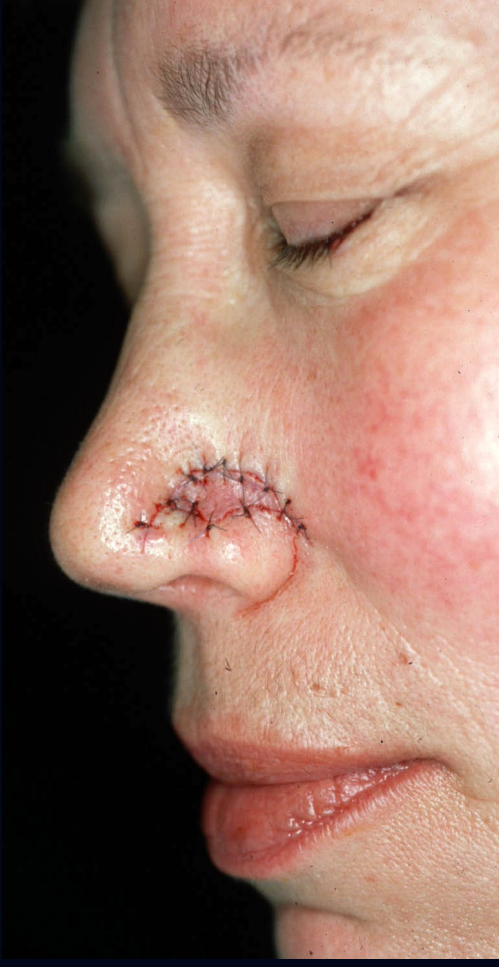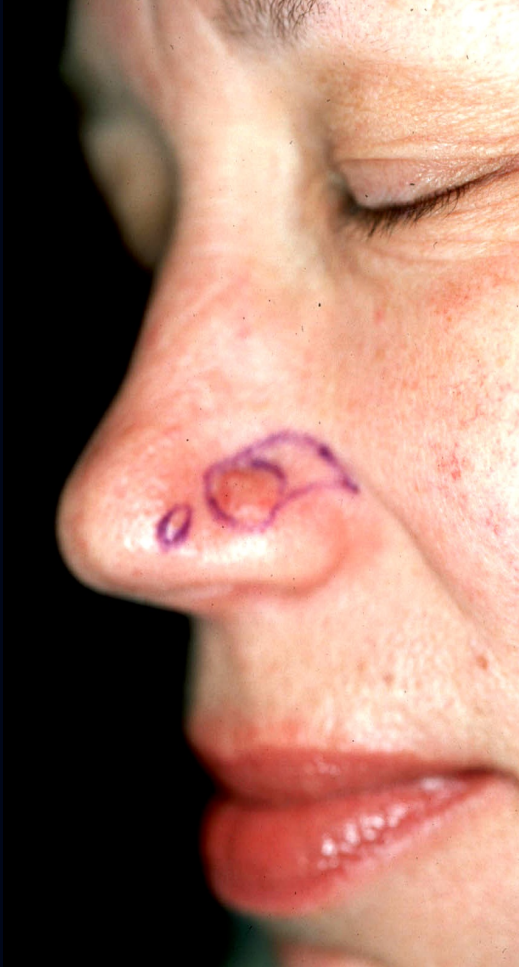- Consider potential donor sites
- Secondary donor defect must be acceptable
- Function is no less important than survival
- Cosmesis is no less important than function
- One-stage reconstruction if possible

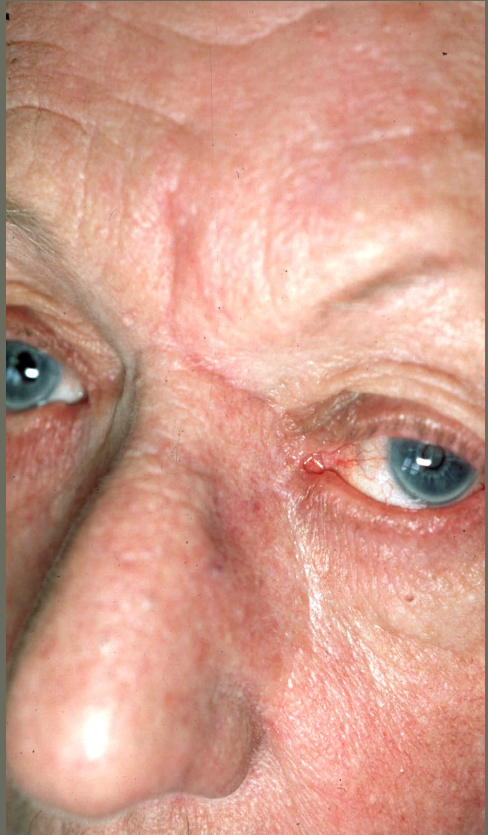
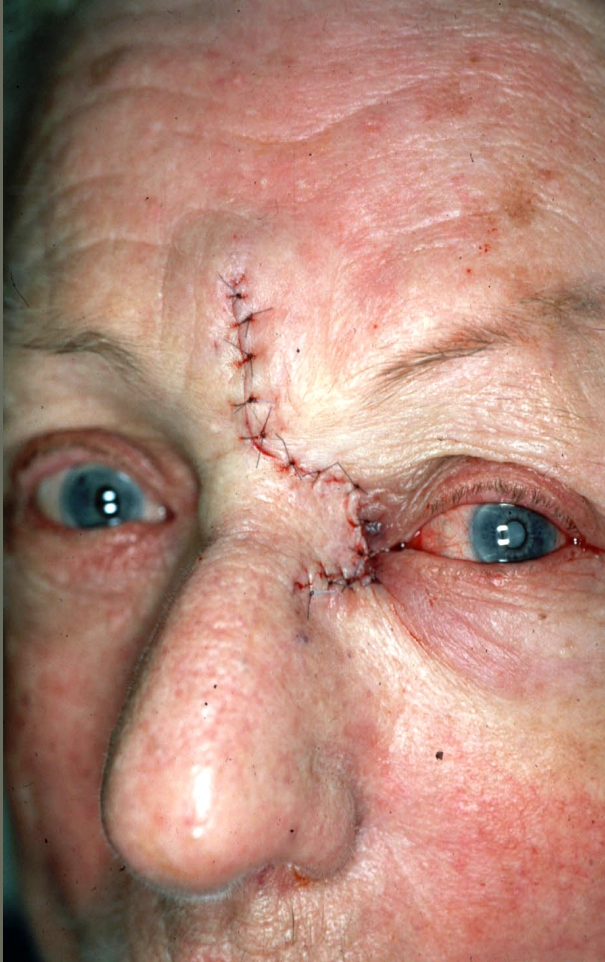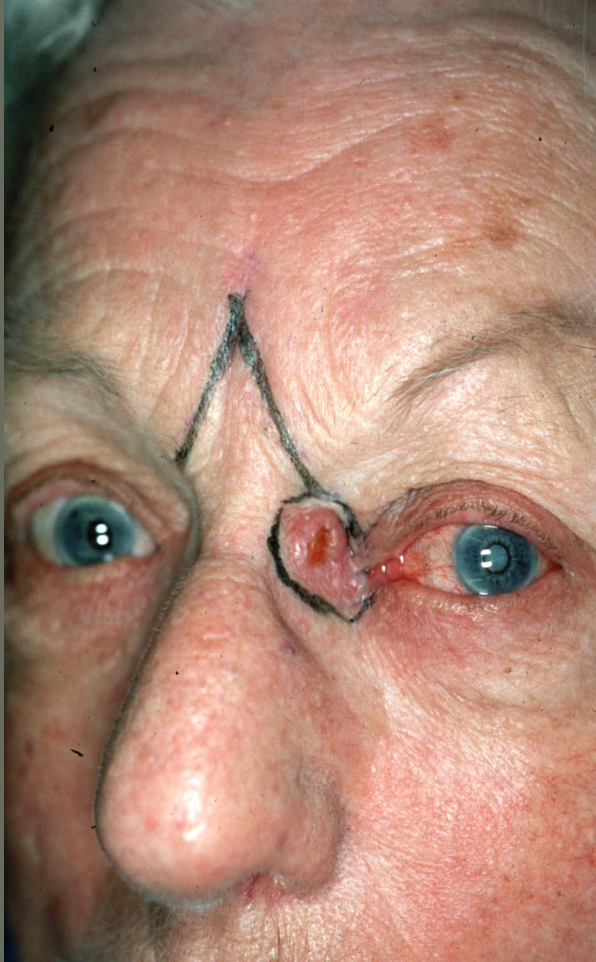
Plastic Surgery is about Cheating

Rob Peter to pay Paul

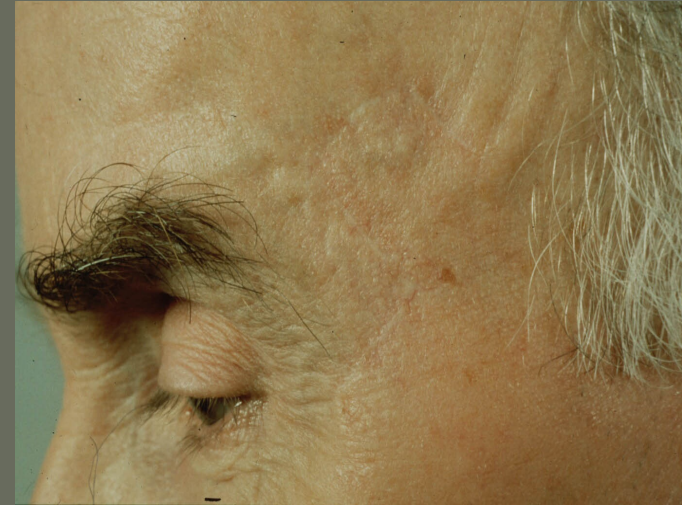
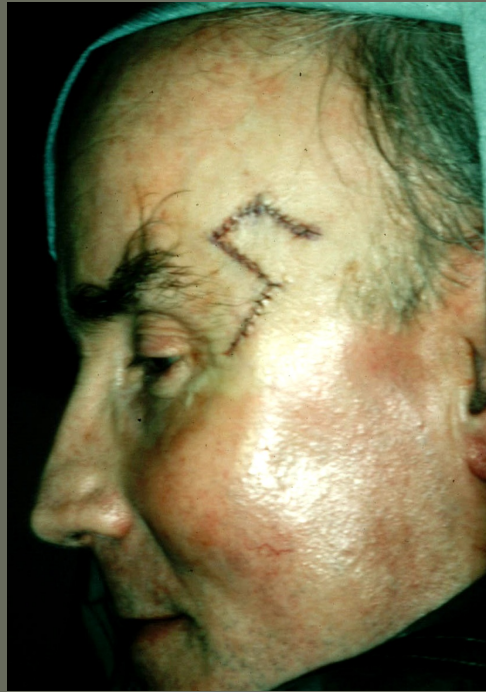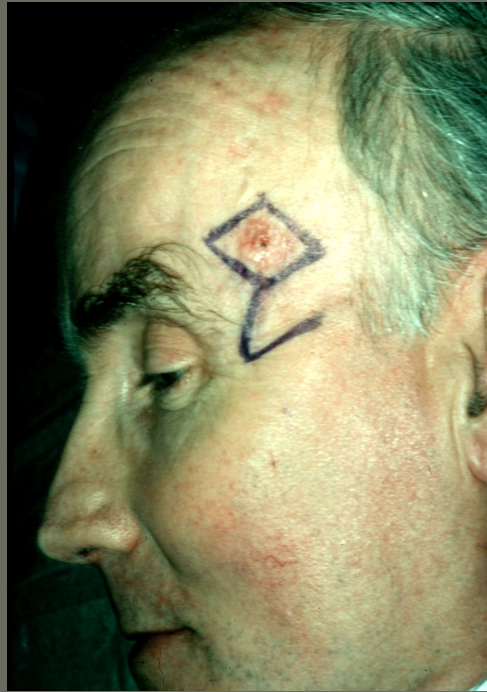V-Y Advancement Flap

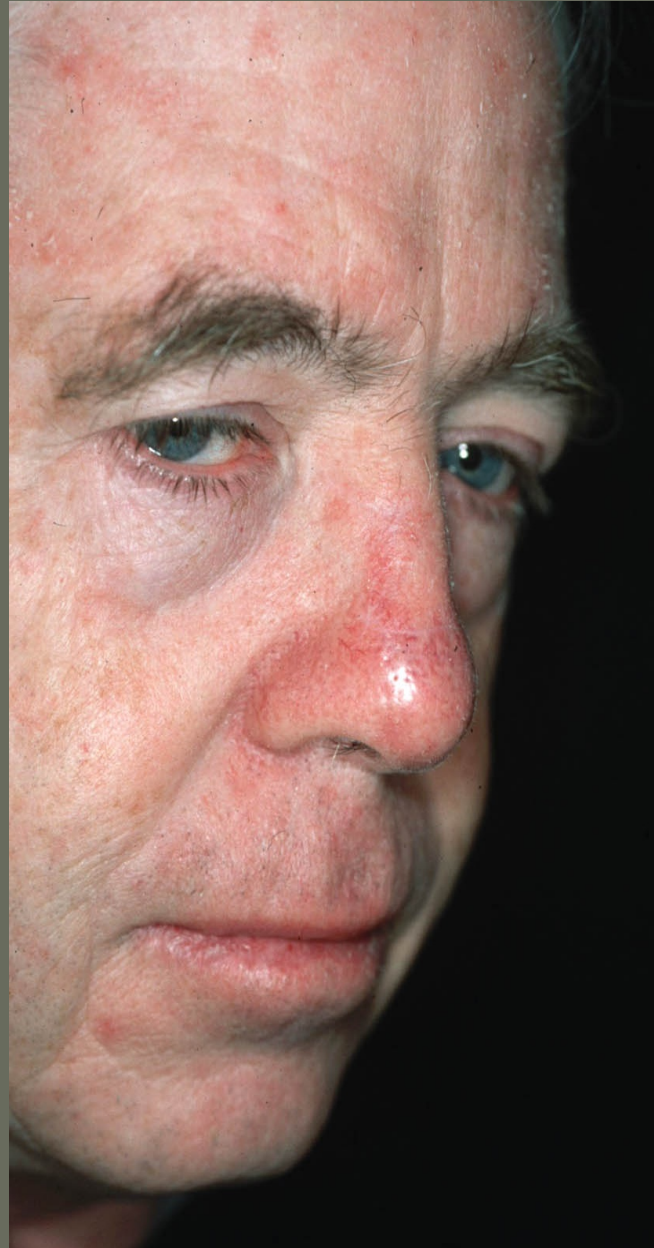
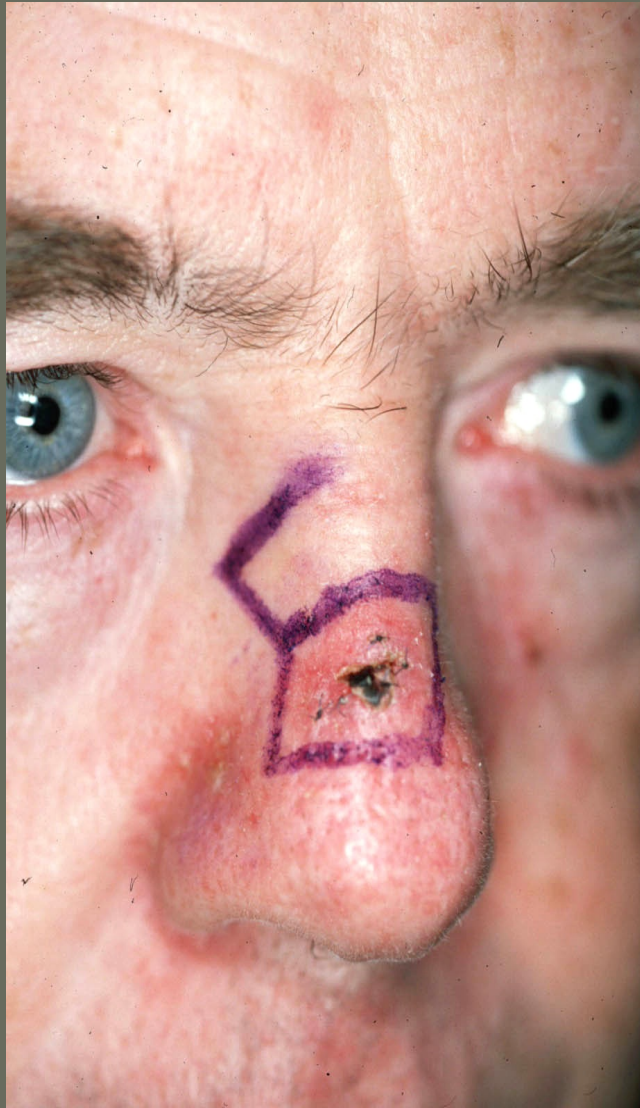




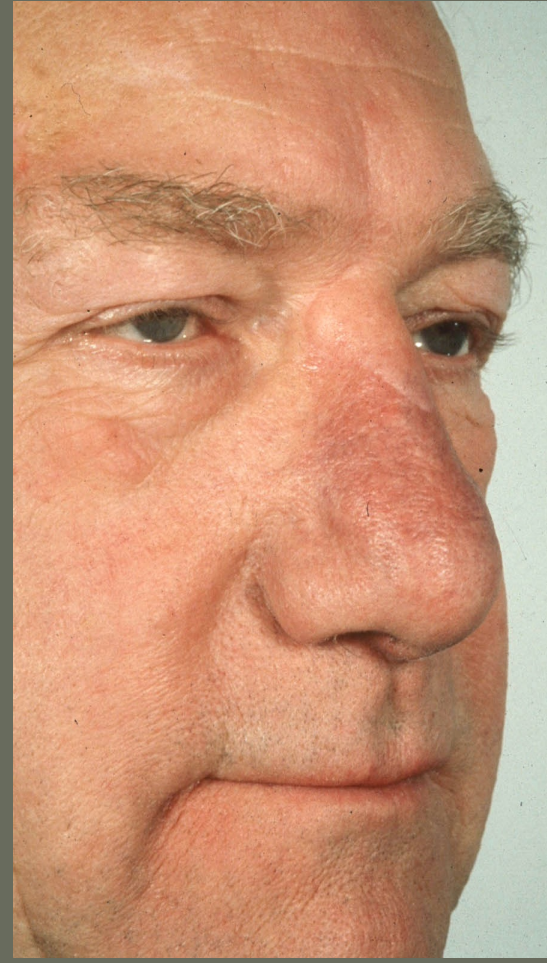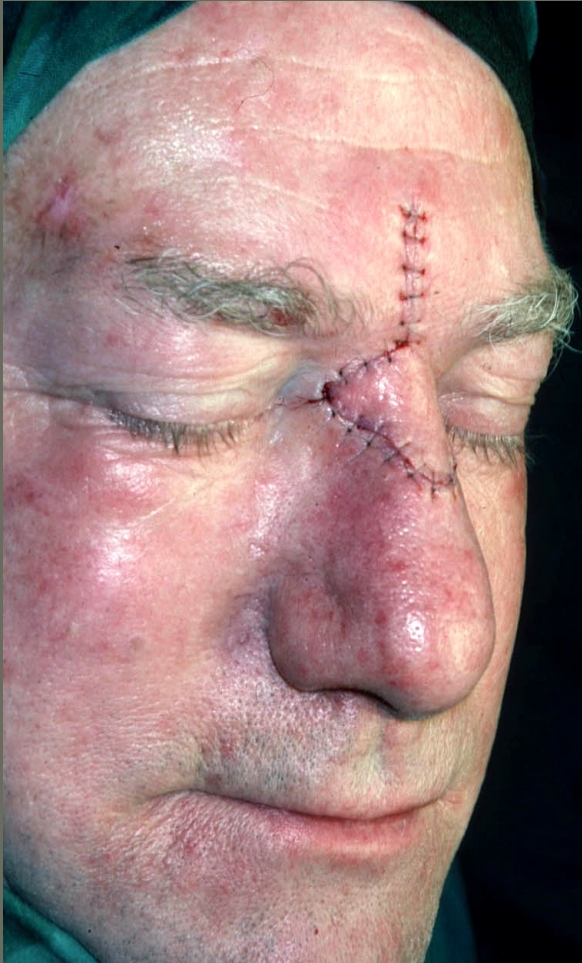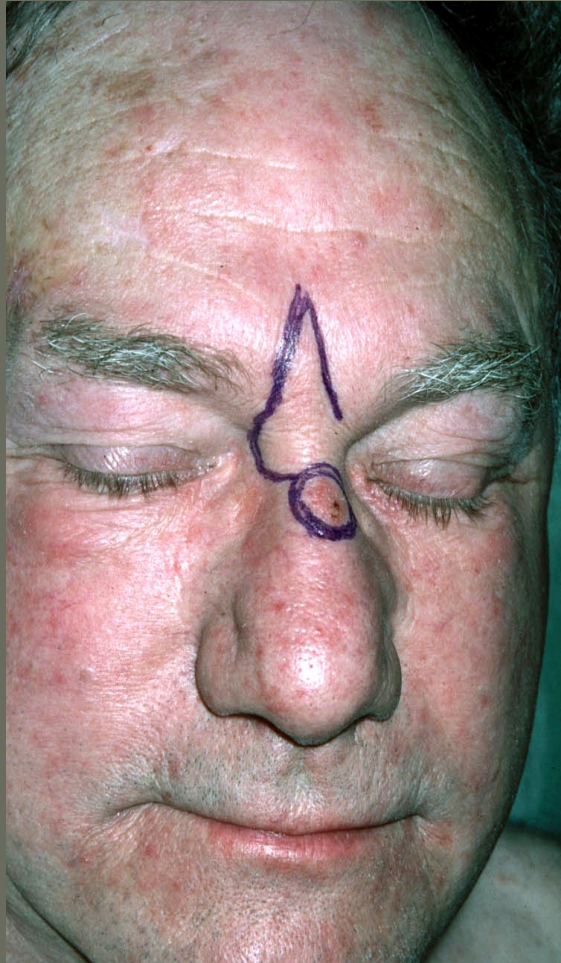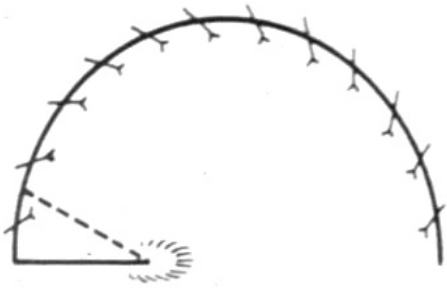
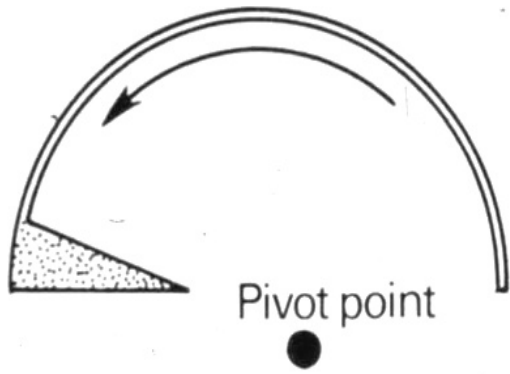
Romboid (Linberg) Flap



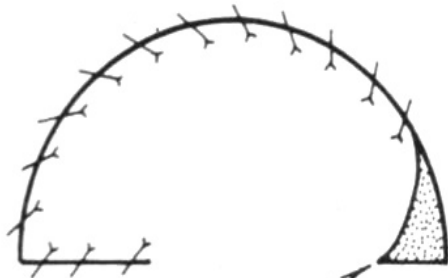

Bilobed Flap

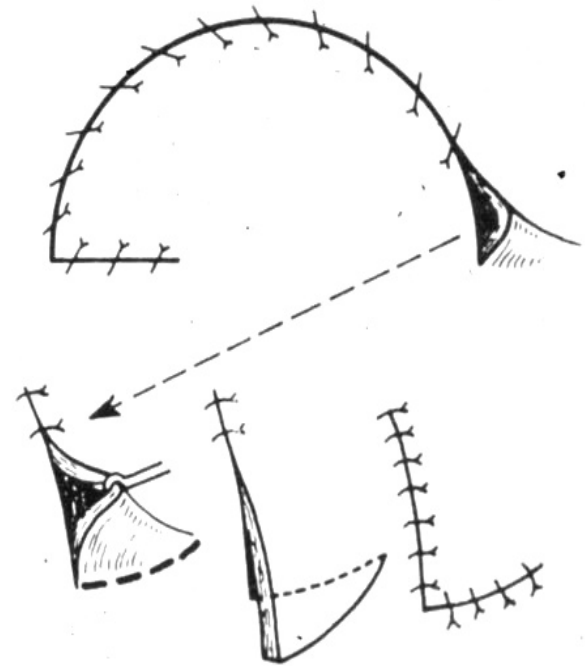
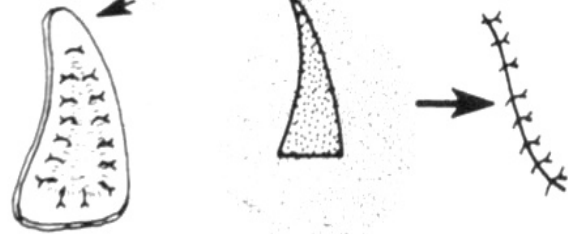




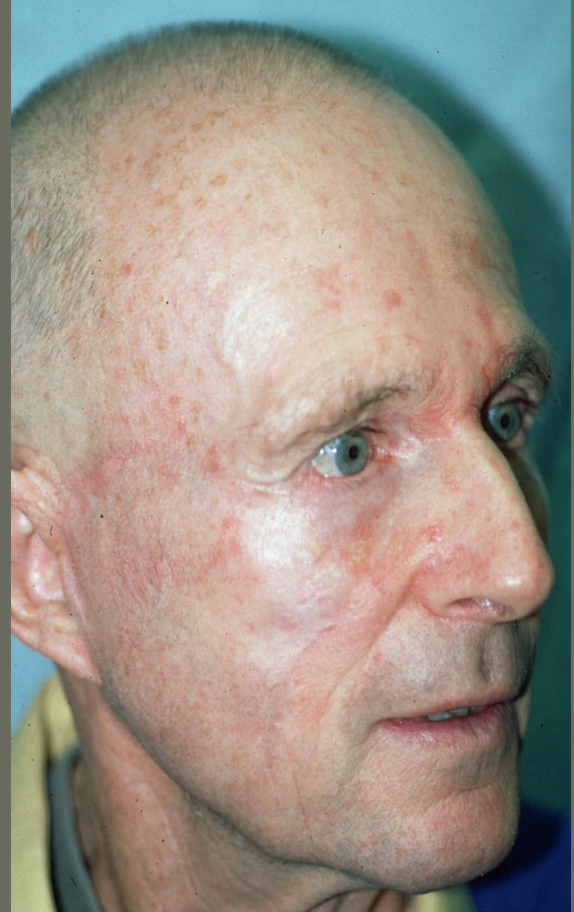
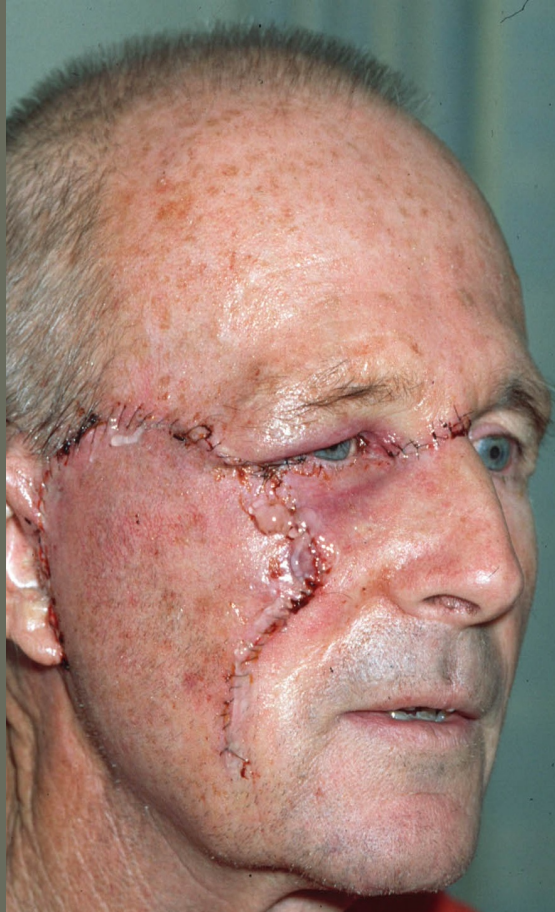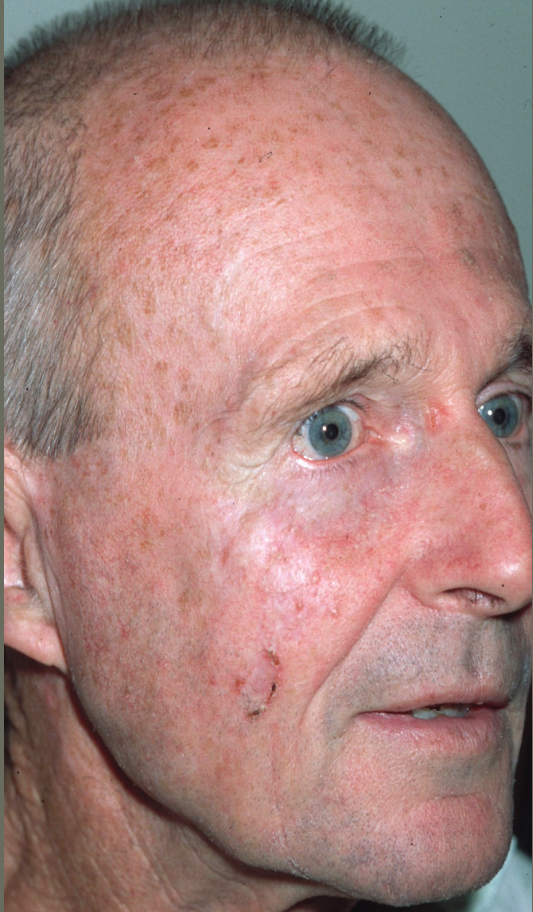A

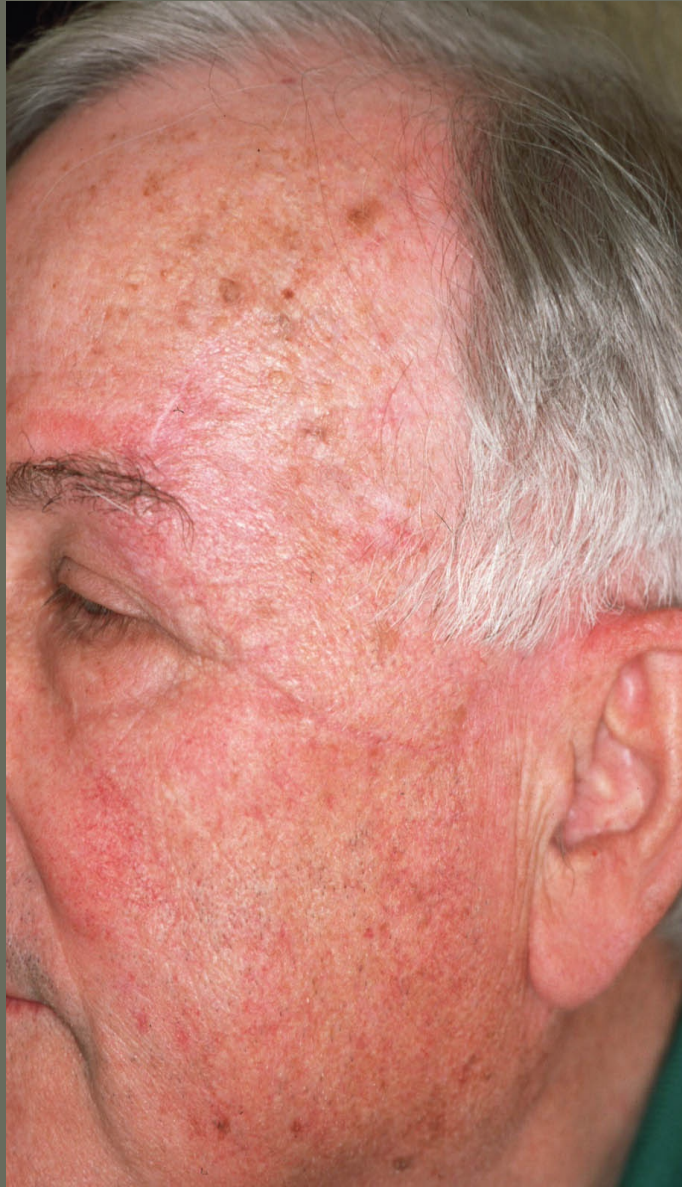
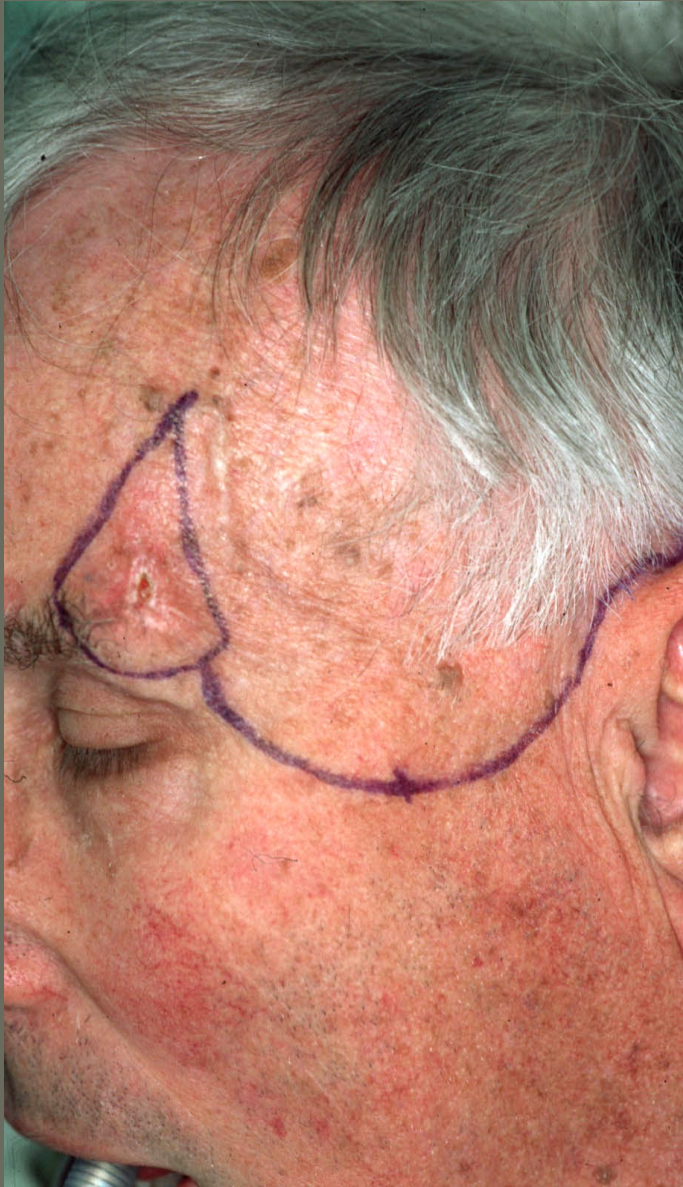
B



C





SUMMARY

- More than one solution for any given reconstructive problem
- Reconstructive ladder/elevator options
- Good surgical technique is essential
- SKIN STRETCHES!