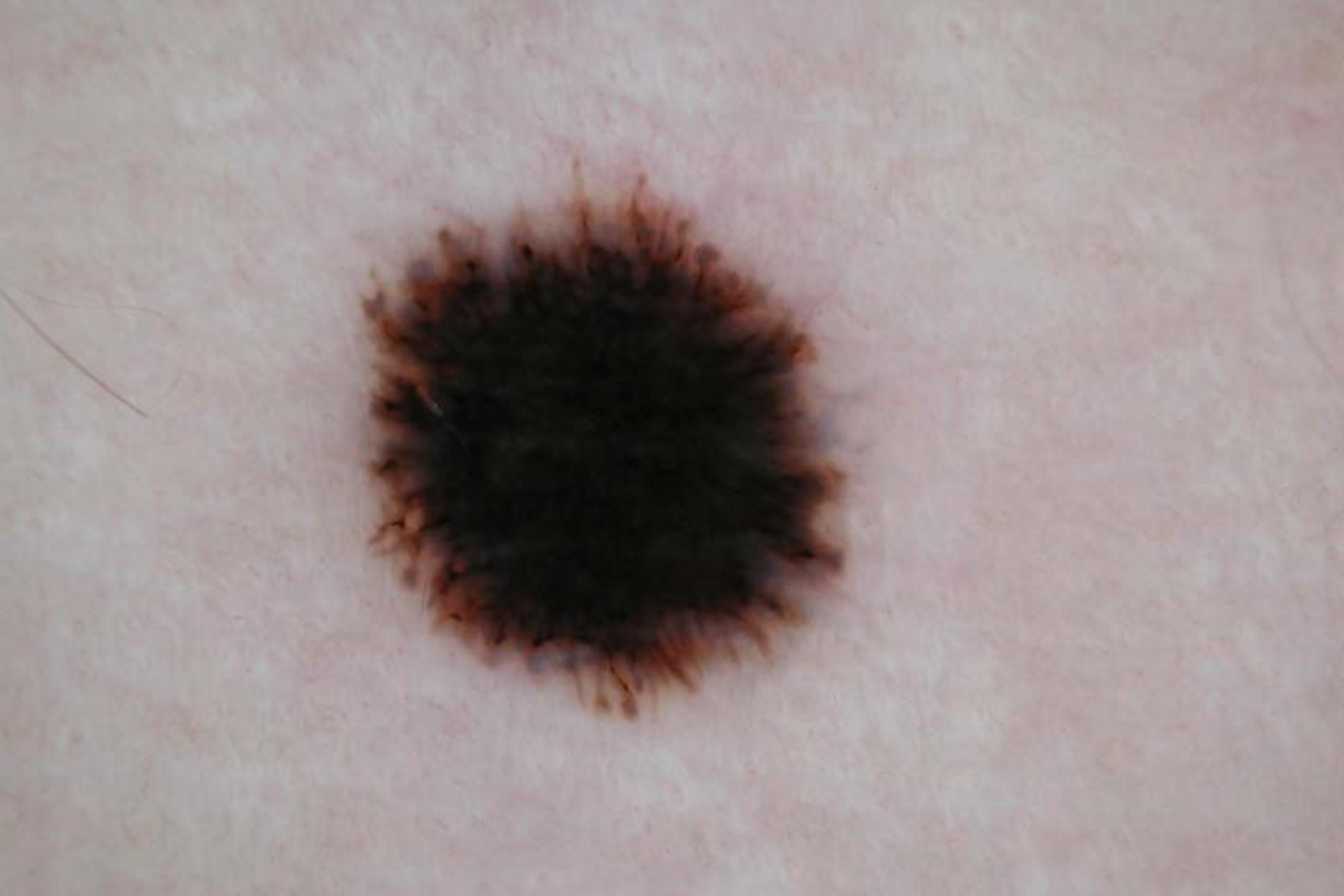

Case n. 1



- **Age:** 23-year-old
- **Sex:** female
- **Location:** right lower leg
- **History:** in the last years lesion showed enlargement and darkening

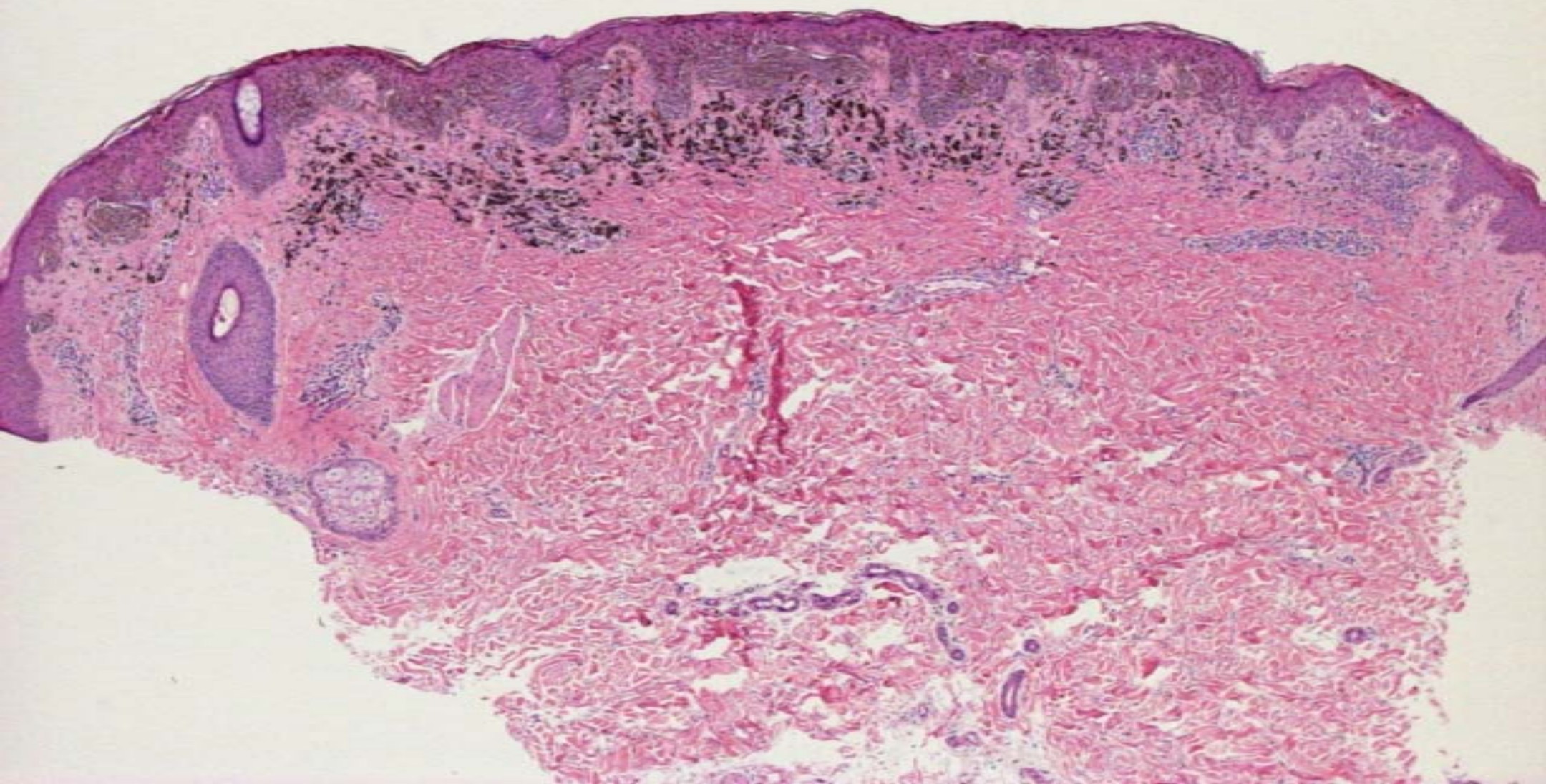


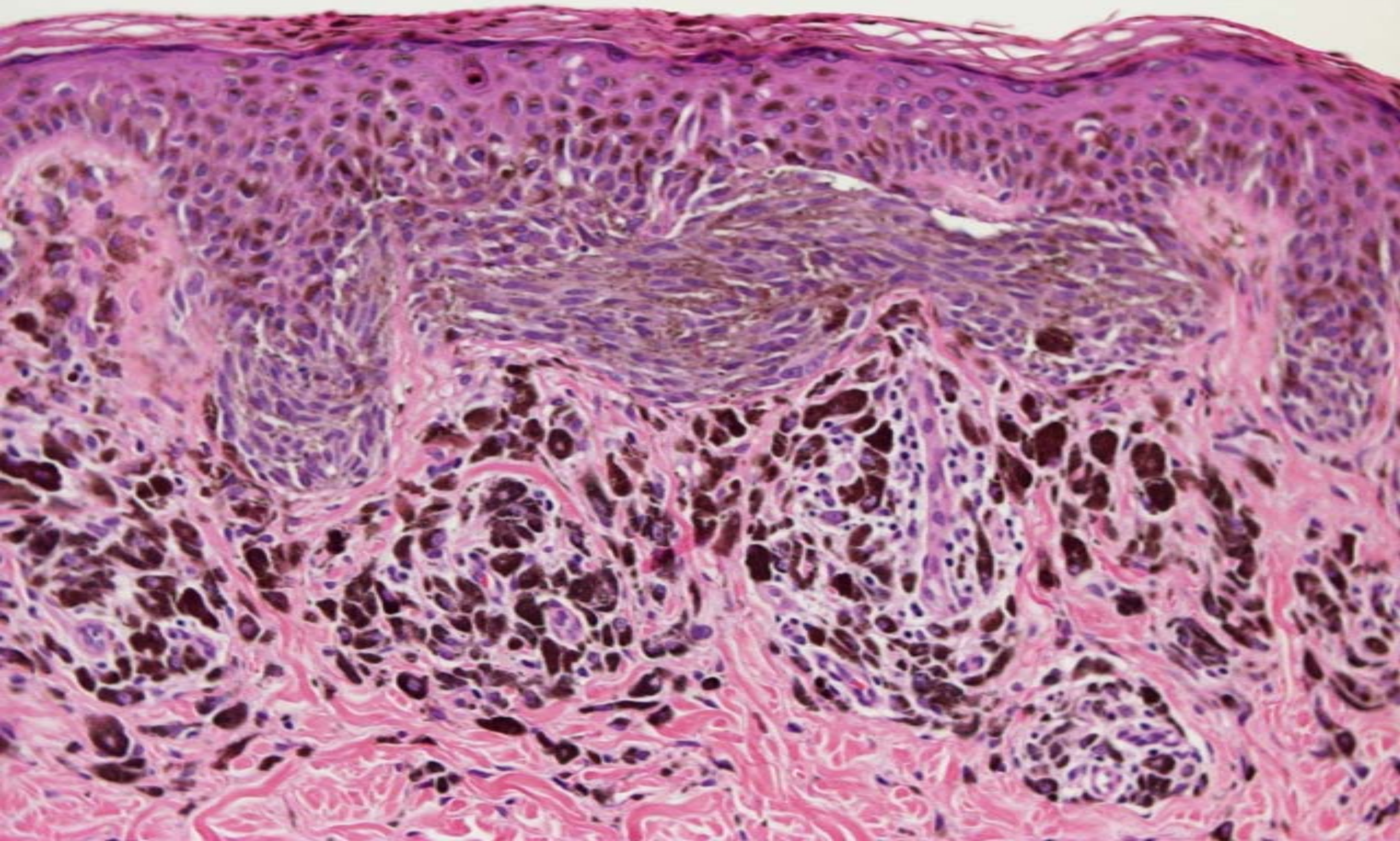


Case n. 1



1. Melanoma
2. Reed nevus
3. Clark nevus (hypermelanotic type)
4. Melanoacanthoma





Case n. 1

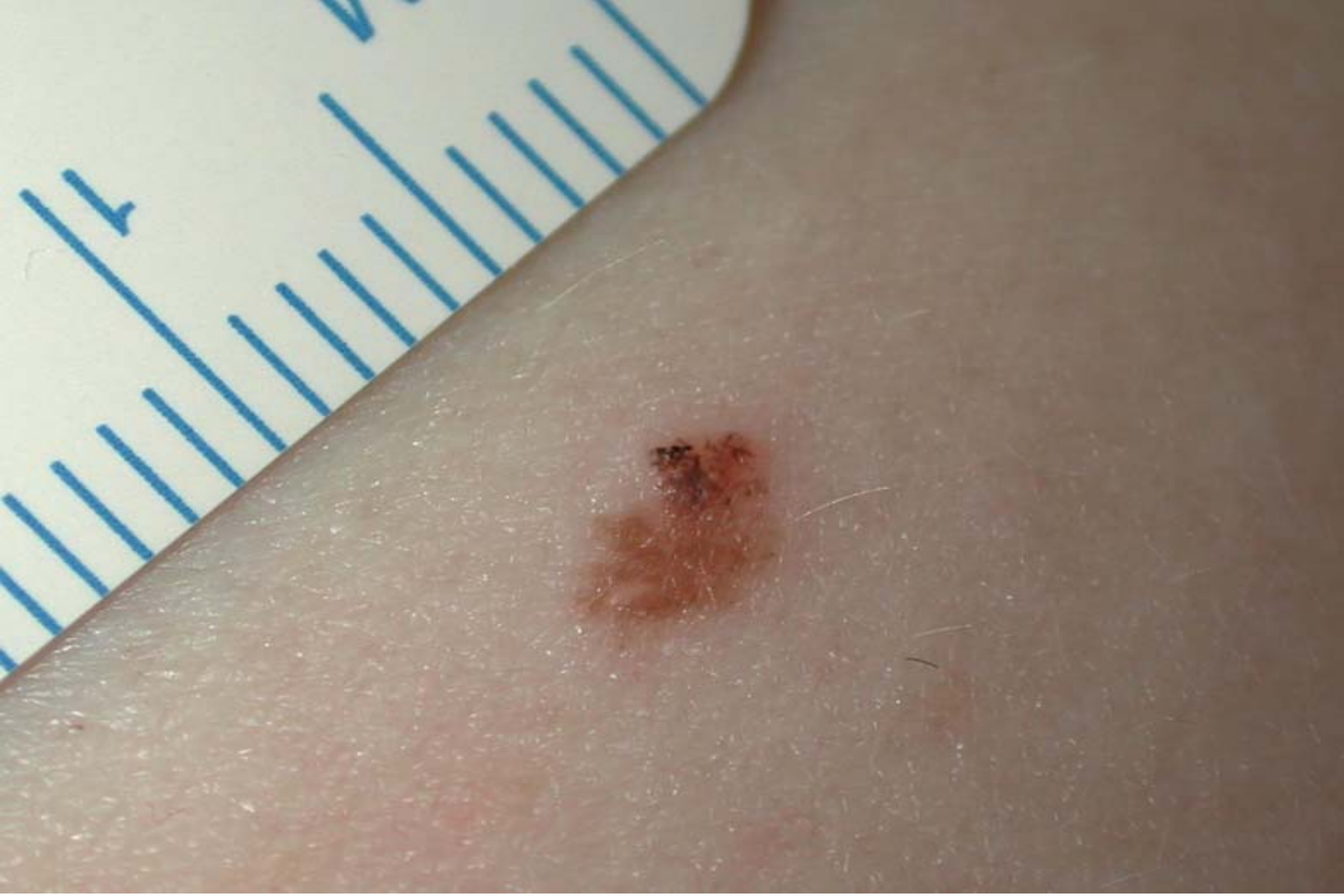

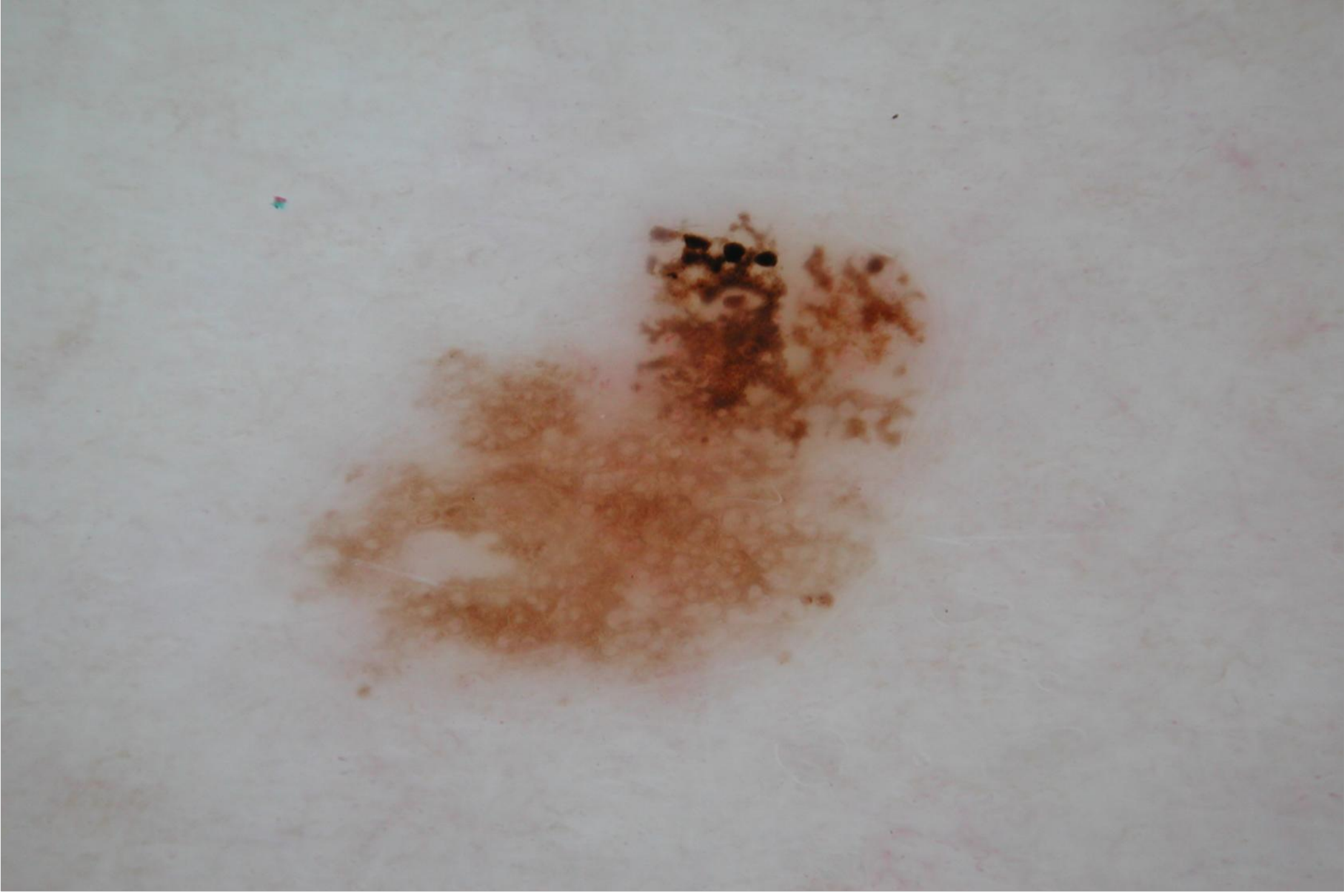
1. Melanoma
2. Reed nevus
3. Clark nevus (hypermelanotic type)
4. Melanoacanthoma

Case n. 2



- ***Age:*** 40-year-old
- ***Sex:*** male
- ***Location:*** abdomen
- ***History:*** patient has never noticed the lesion

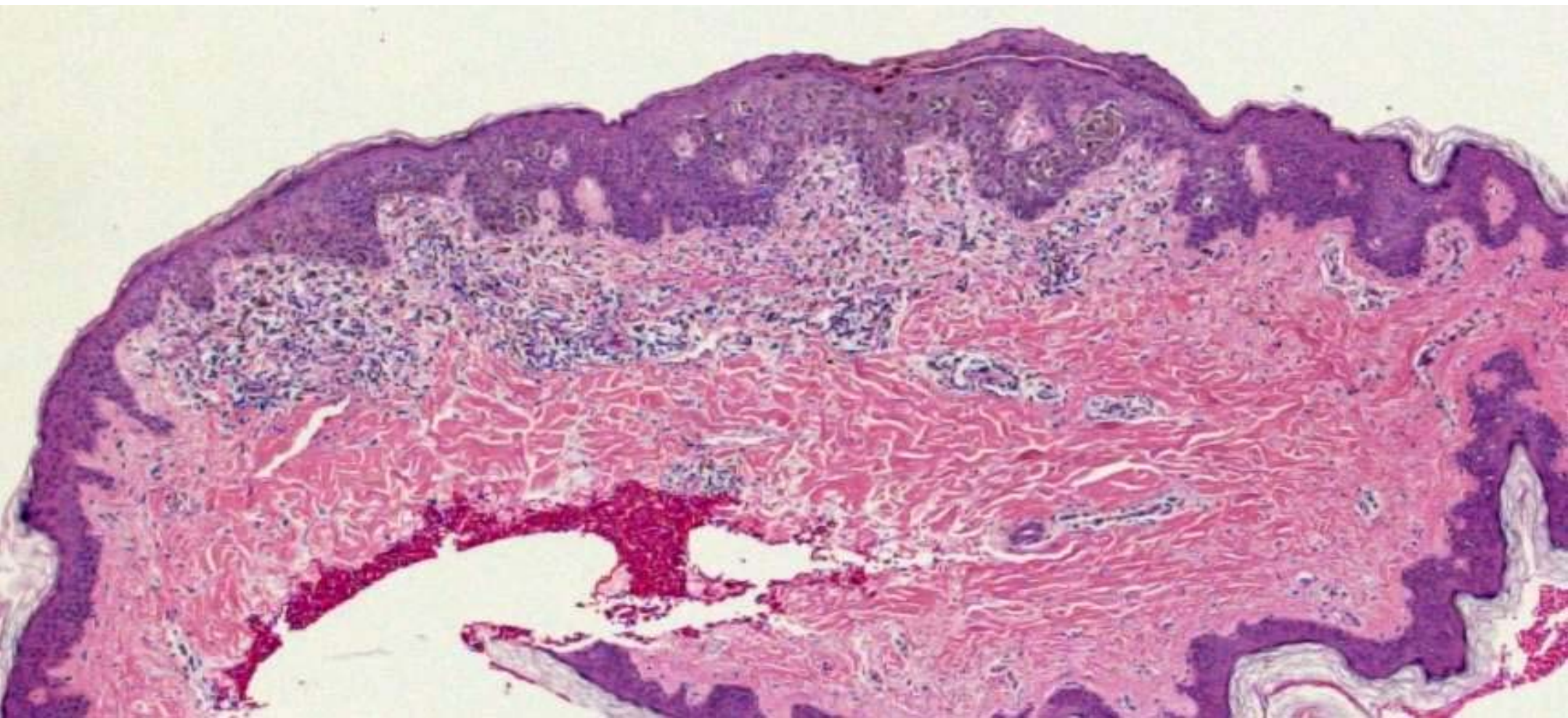


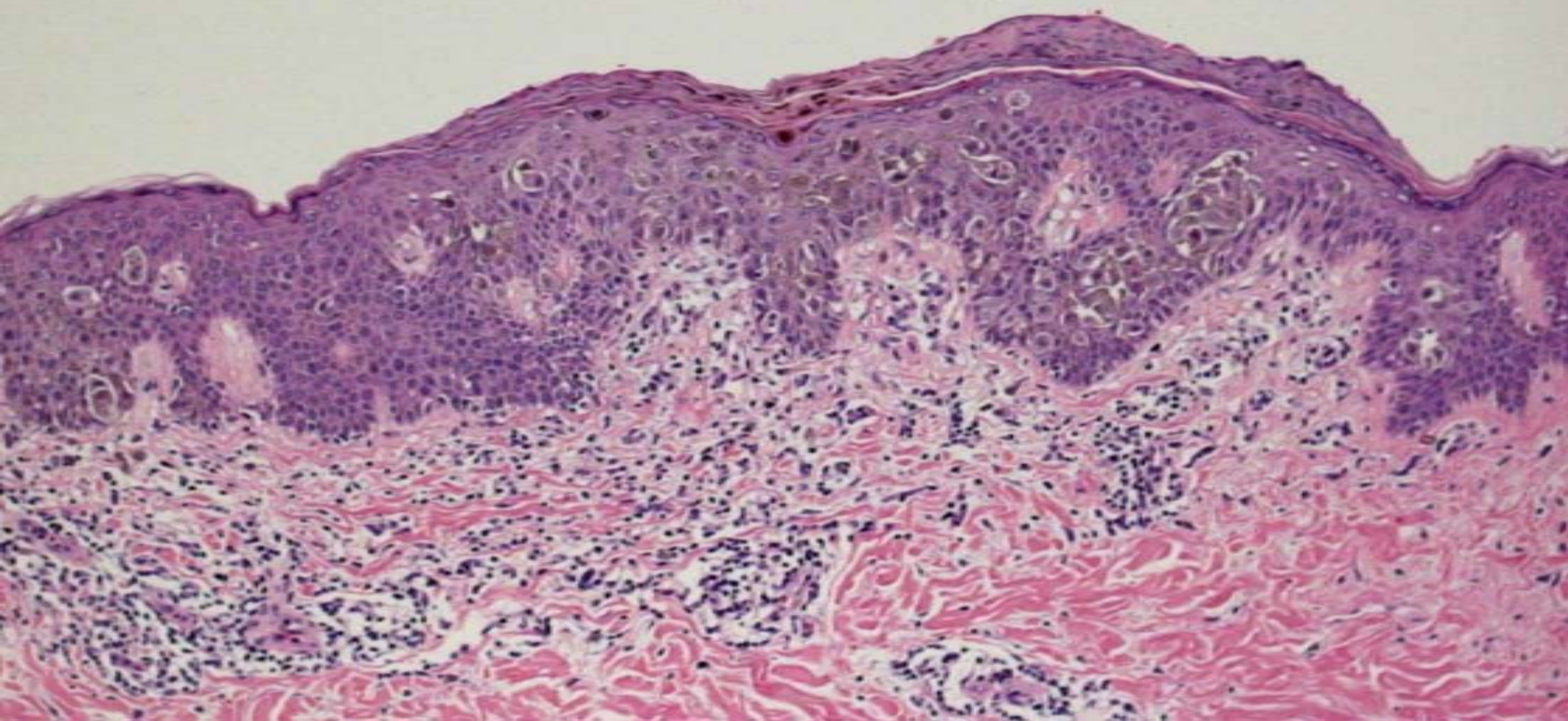


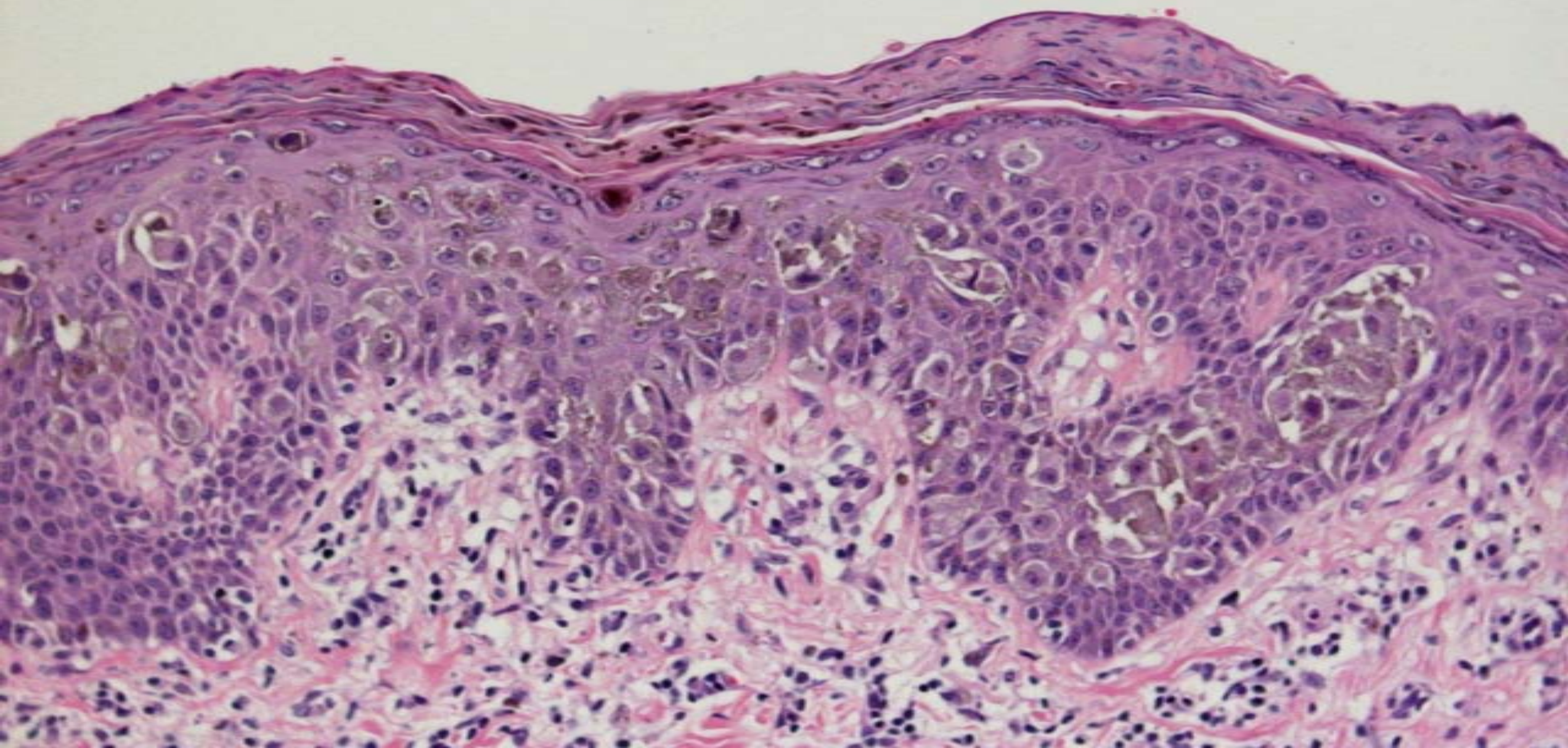


Case n. 2

1. Melanoma (melanoma in situ)
2. Combined nevus (Clark + Reed)
3. Clark nevus (peripheral hyperpigmented type)
4. Seborrheic keratosis (reticular type; arising within a solar lentigo)







Case n. 2

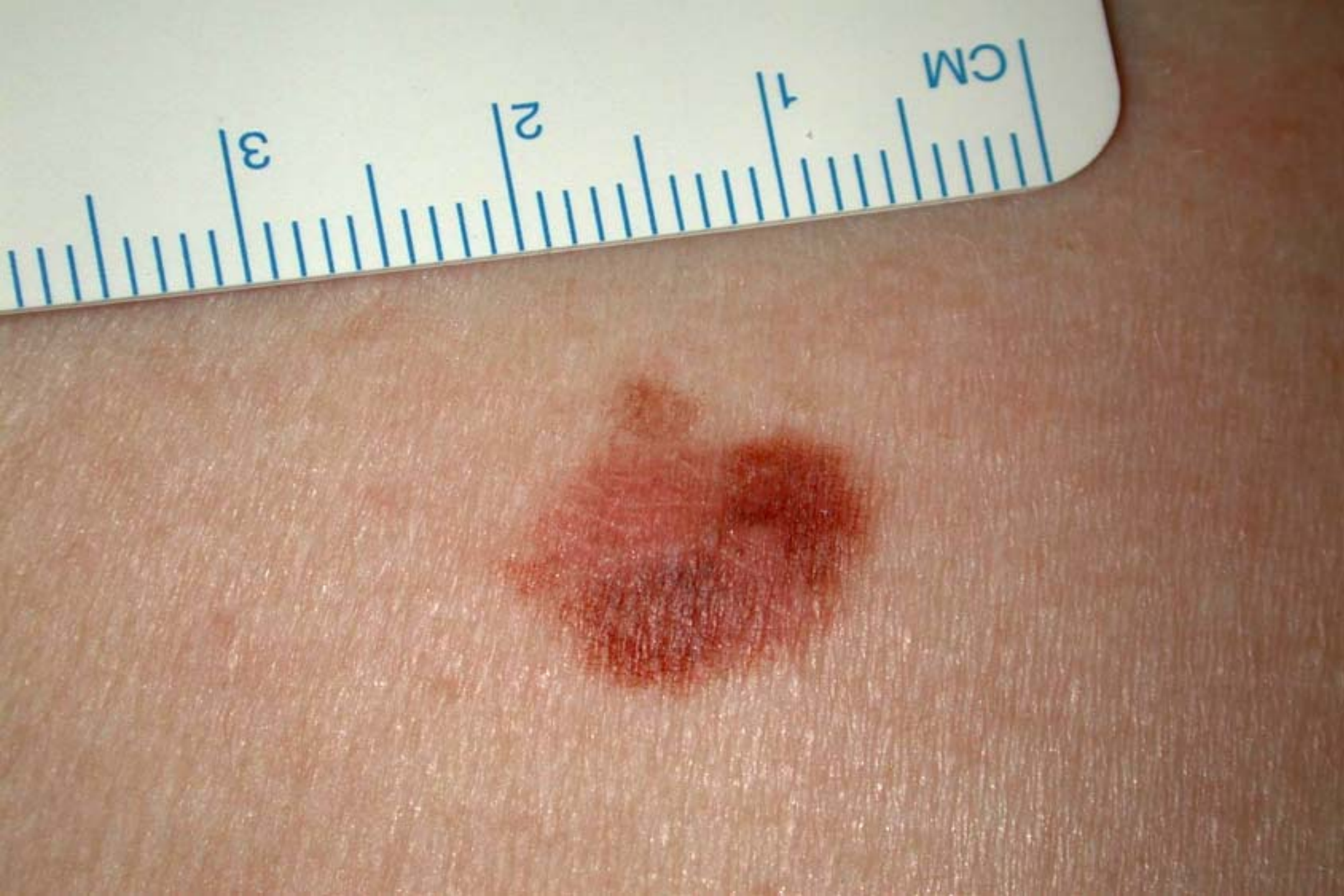

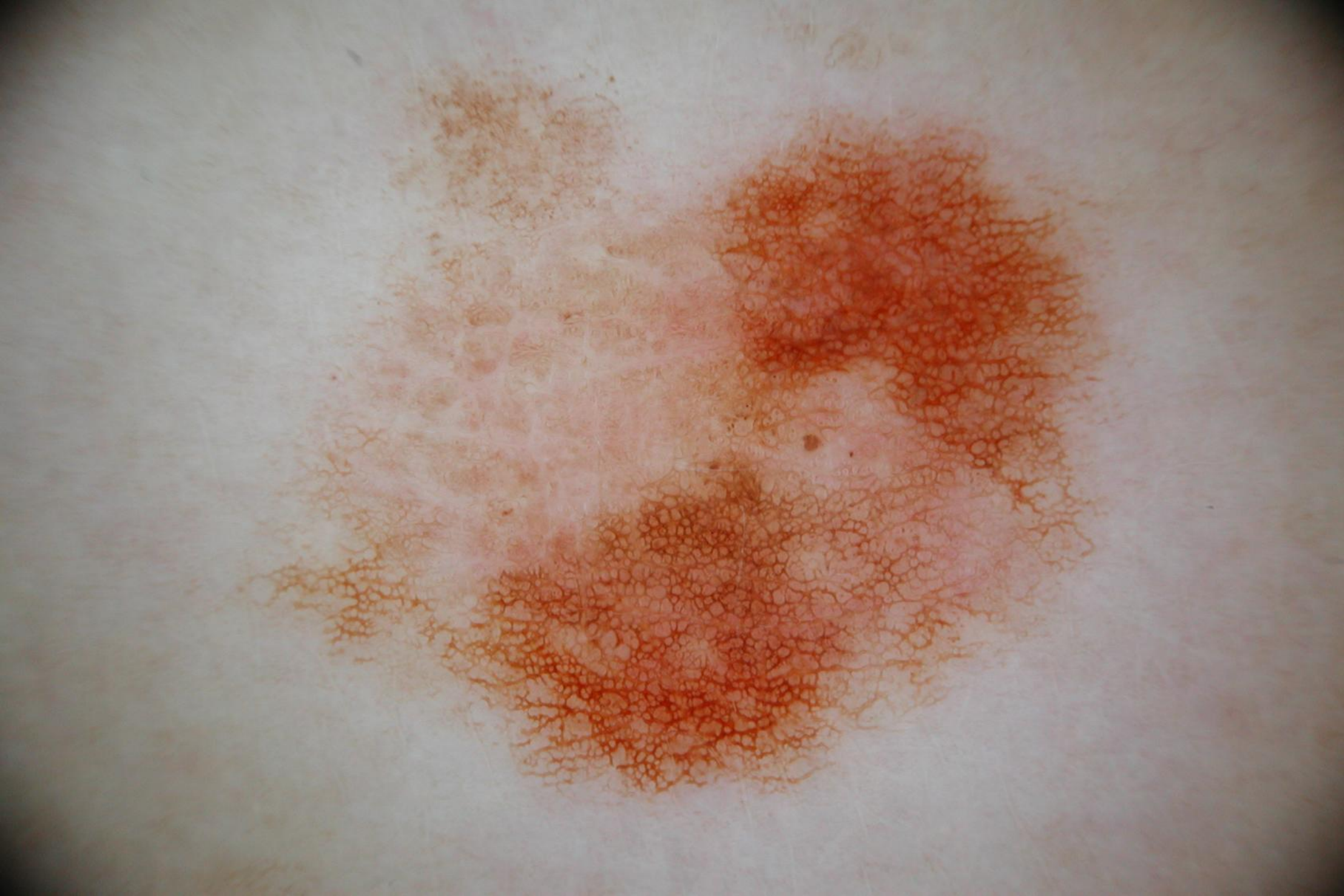1. Melanoma (melanoma in situ)
2. Combined nevus (Clark + Reed)
3. Clark nevus (peripheral hyperpigmented type)
4. Seborrheic keratosis (reticular type; arising within a solar lentigo)

Case n. 3



- ***Age:*** 51-year-old
- ***Sex:*** female
- ***Location:*** abdomen
- ***History:*** lesion present for many years

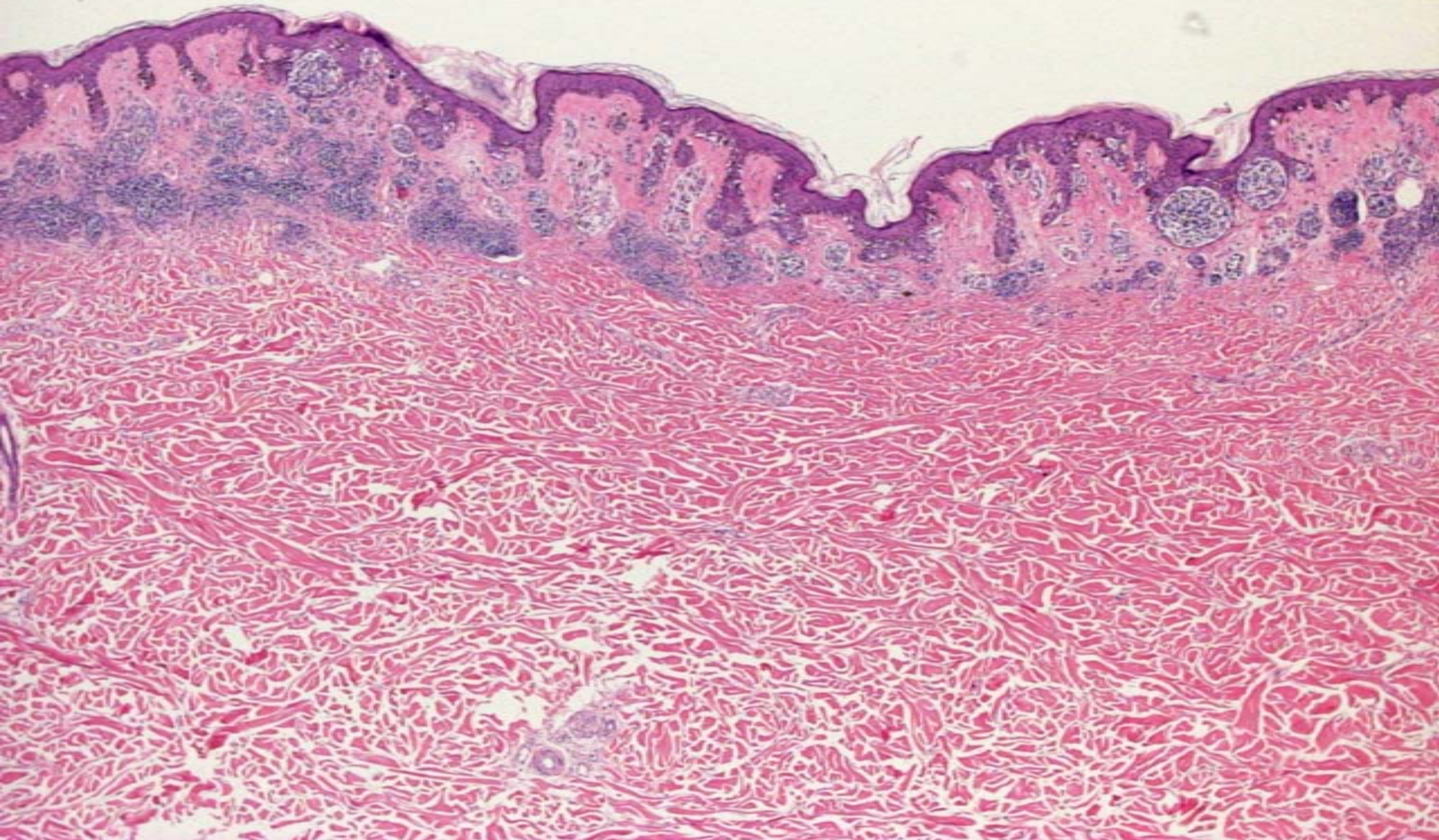


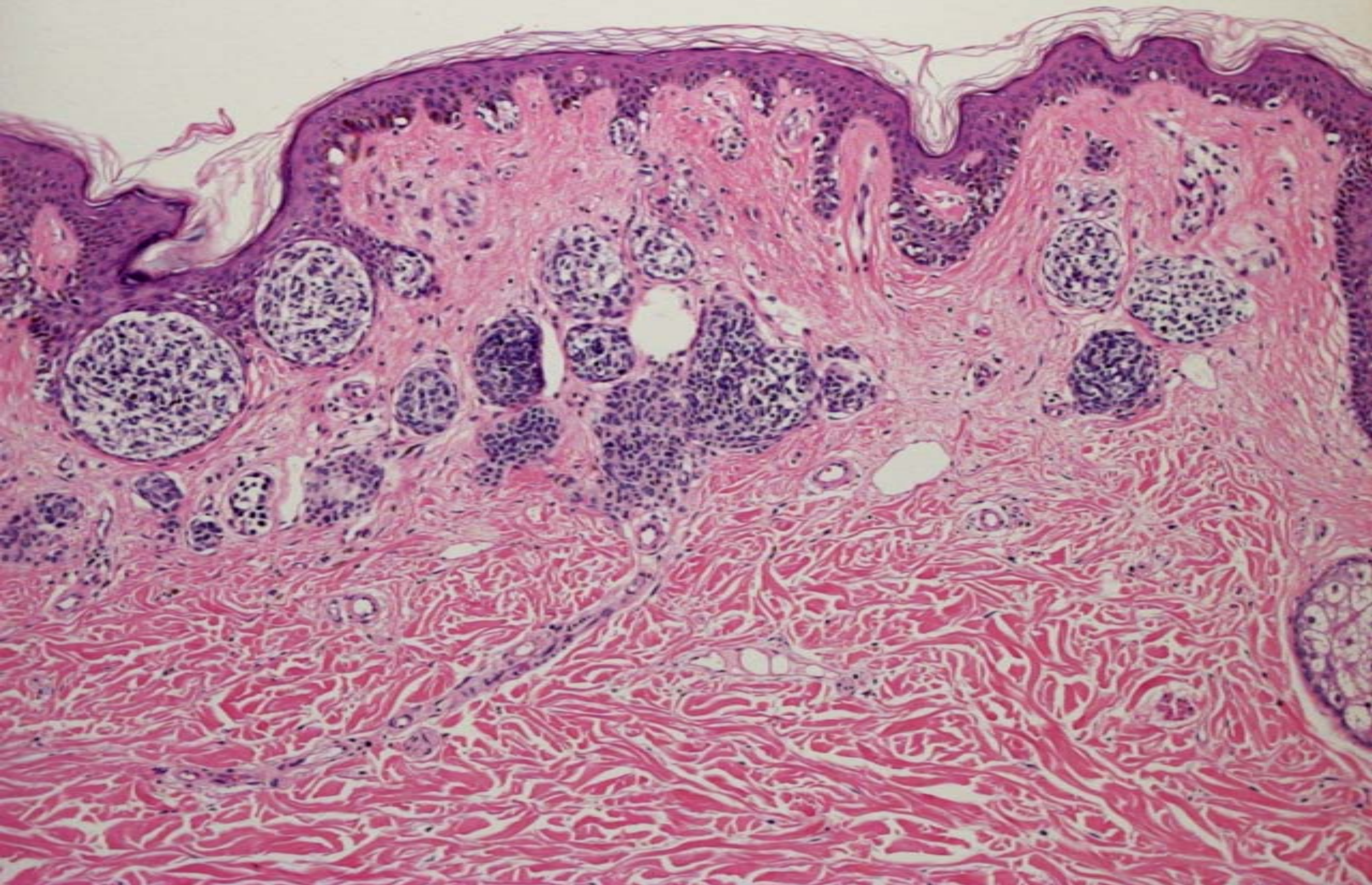




Case n. 3

1. Seborrheic keratosis (reticular type; arising within a solar lentigo)
2. Congenital nevus
3. Melanoma
4. Clark nevus





Case n. 3



1. Seborrheic keratosis (reticular type; arising within a solar lentigo)
2. Congenital nevus
3. Melanoma
4. Clark nevus



Case n. 4

- ***Age:*** 37-year-old
- ***Sex:*** female
- ***Location:*** left thigh
- ***History:*** previous melanoma excised one year ago from the left lower leg



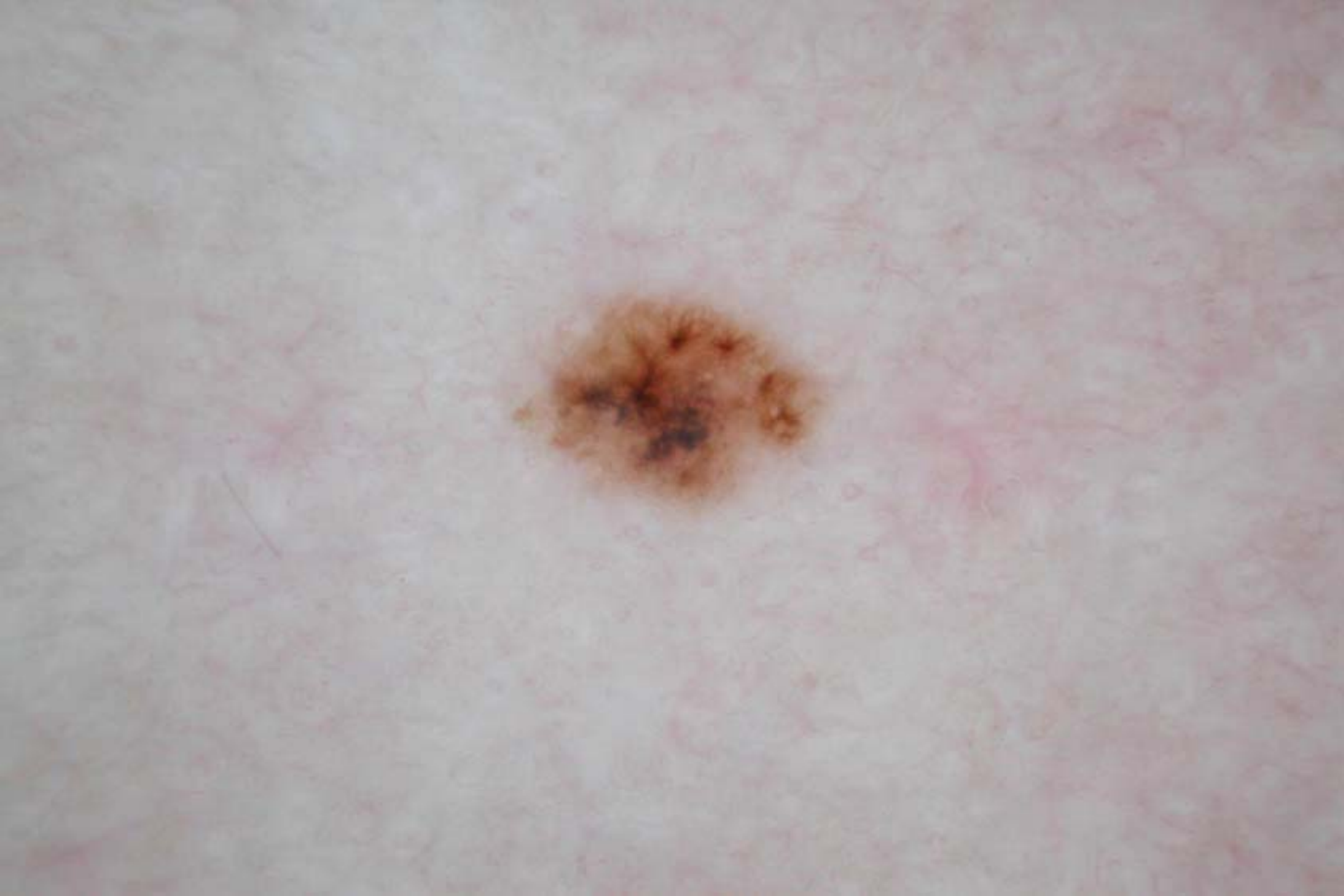9

CM

1

2

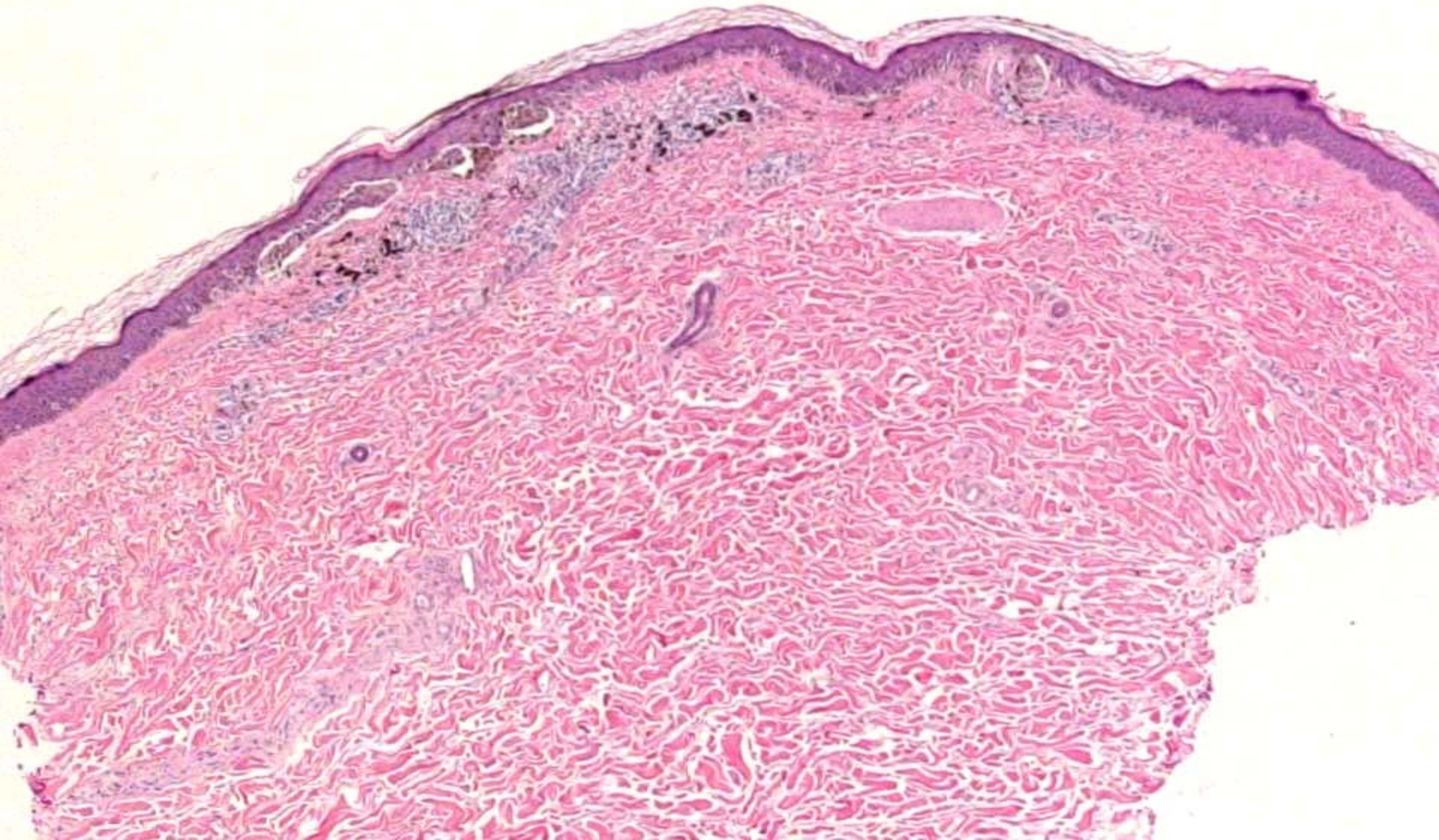


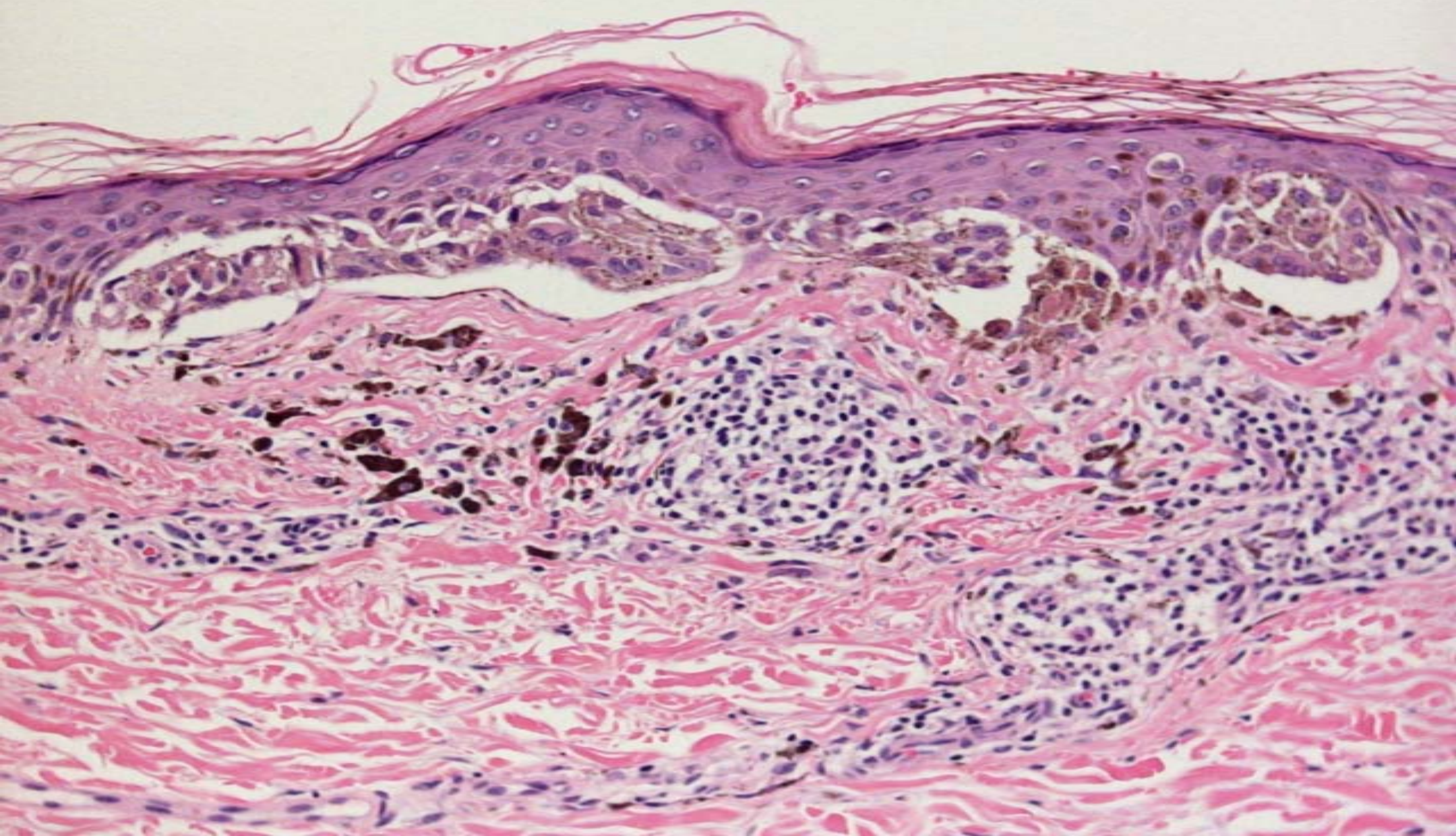


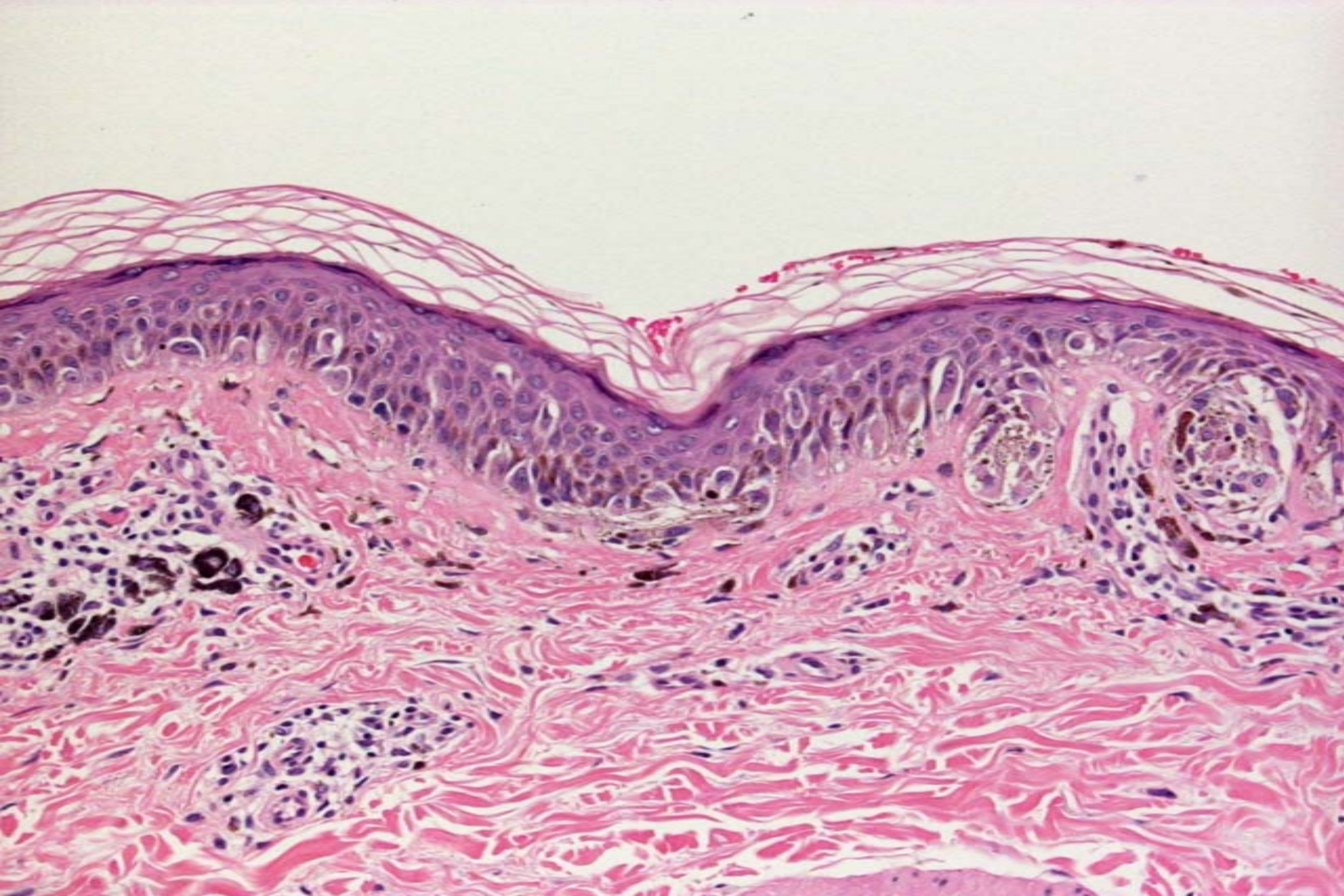
Case n. 4



1. Melanoma in situ
2. Spitz nevus
3. Clark nevus
4. Melanoma metastasis







Case n. 4

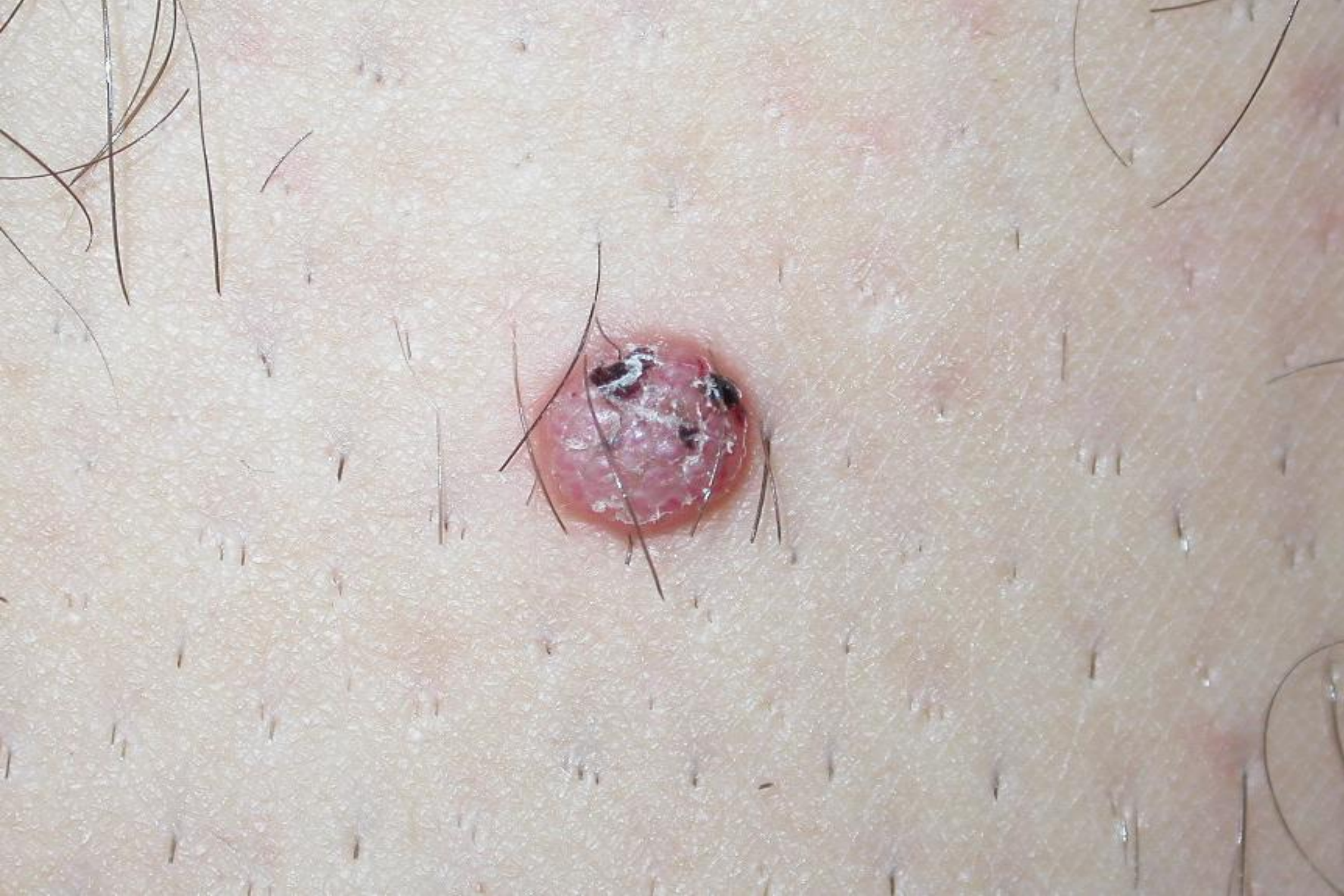

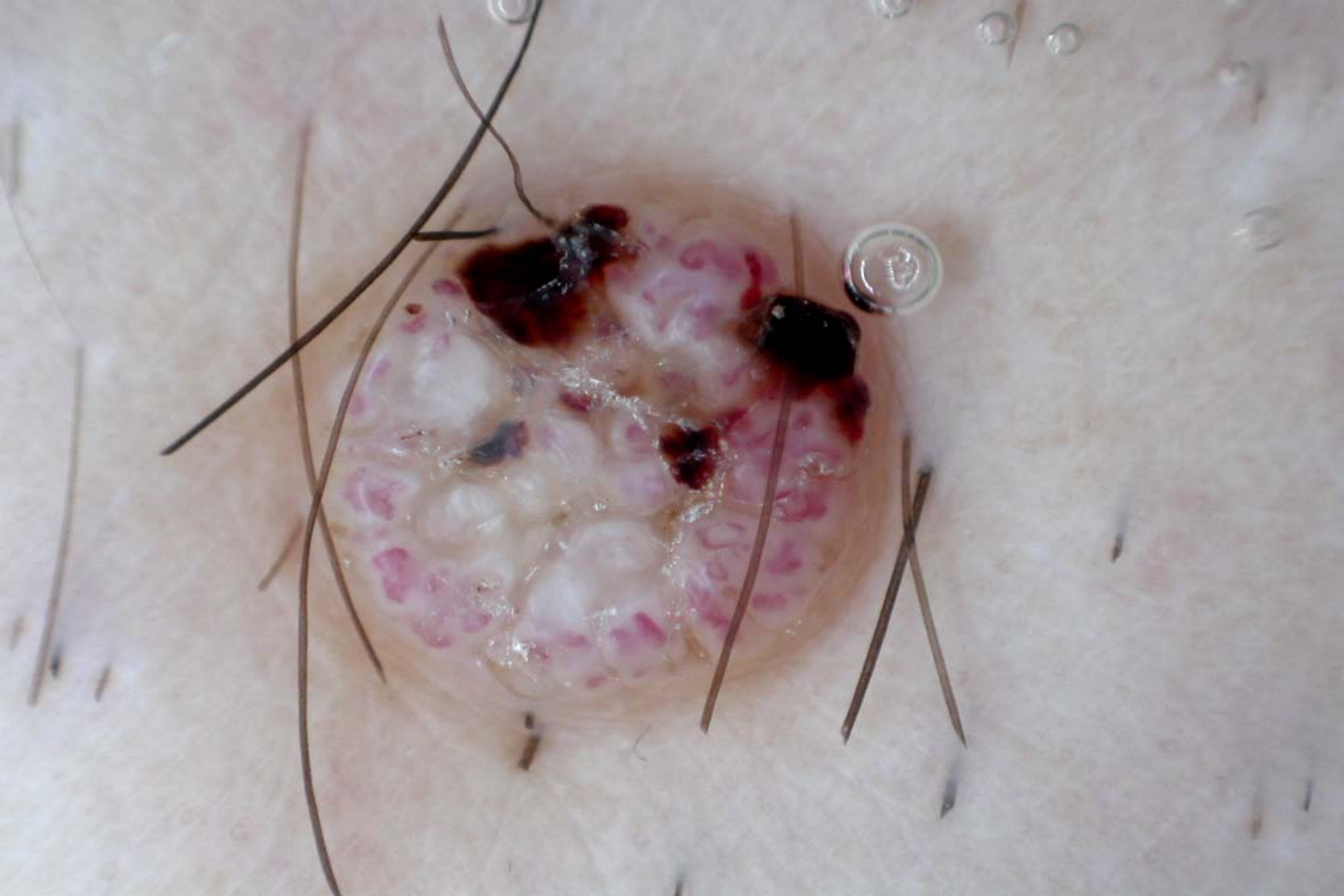1. Melanoma in situ
2. Spitz nevus
3. Clark nevus
4. Melanoma metastasis

Case n. 5



- ***Age:*** 28-year-old
- ***Sex:*** male
- ***Location:*** lower leg
- ***History:*** lesion appeared recently (2 months)

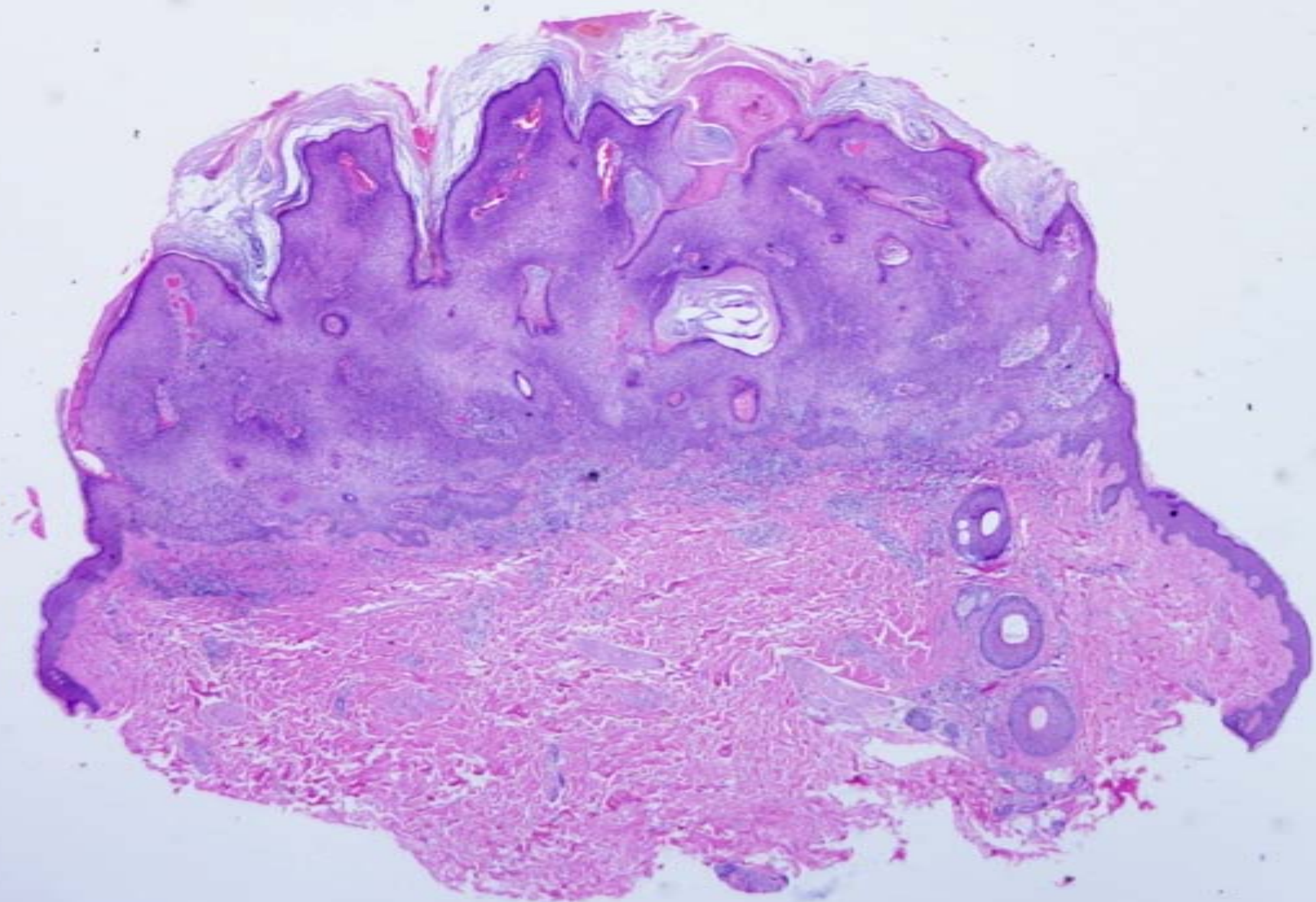


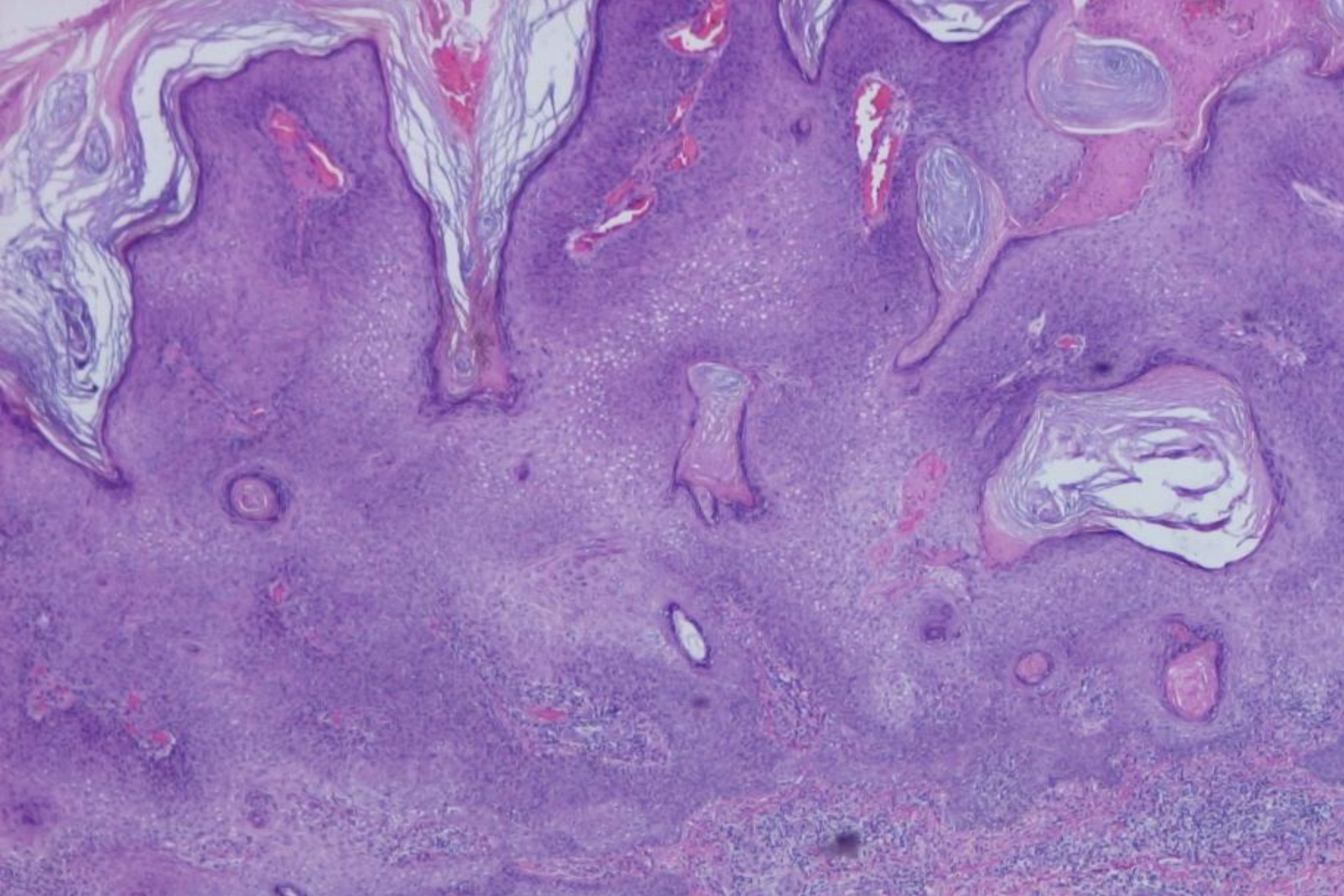


Case n. 5



1. Amelanotic melanoma
2. Pyogenic granuloma
3. Irritated viral wart
4. Keratoacanthoma





Case n. 5

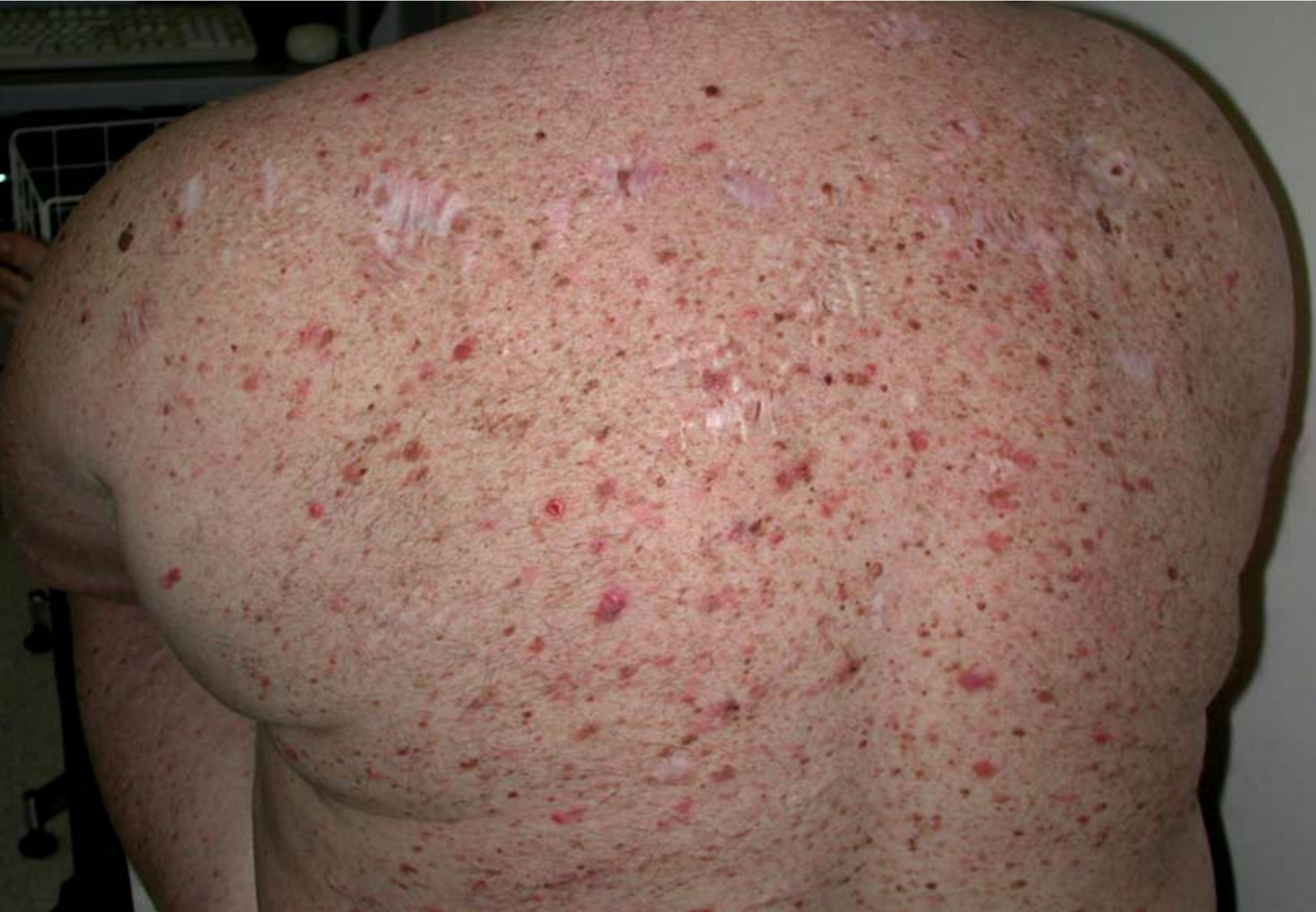

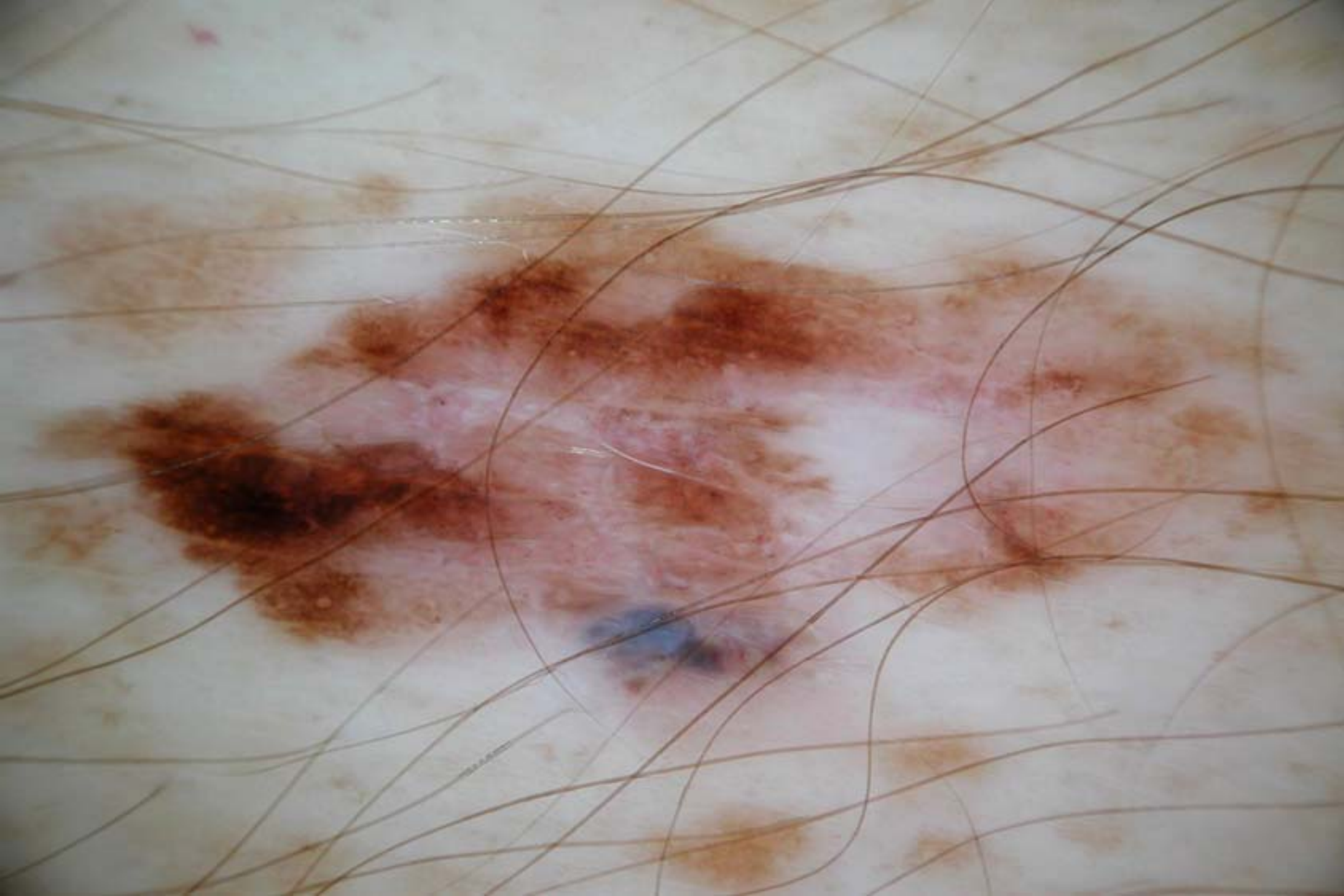1. Amelanotic melanoma
2. Pyogenic granuloma
3. Irritated viral wart
4. Keratoacanthoma



Case n. 6

- ***Age:*** 36-year-old
- ***Sex:*** male
- ***Location:*** back
- ***History:*** patient with xeroderma pigmentosum; previous excisions of numerous melanomas, BCC's and SCC's

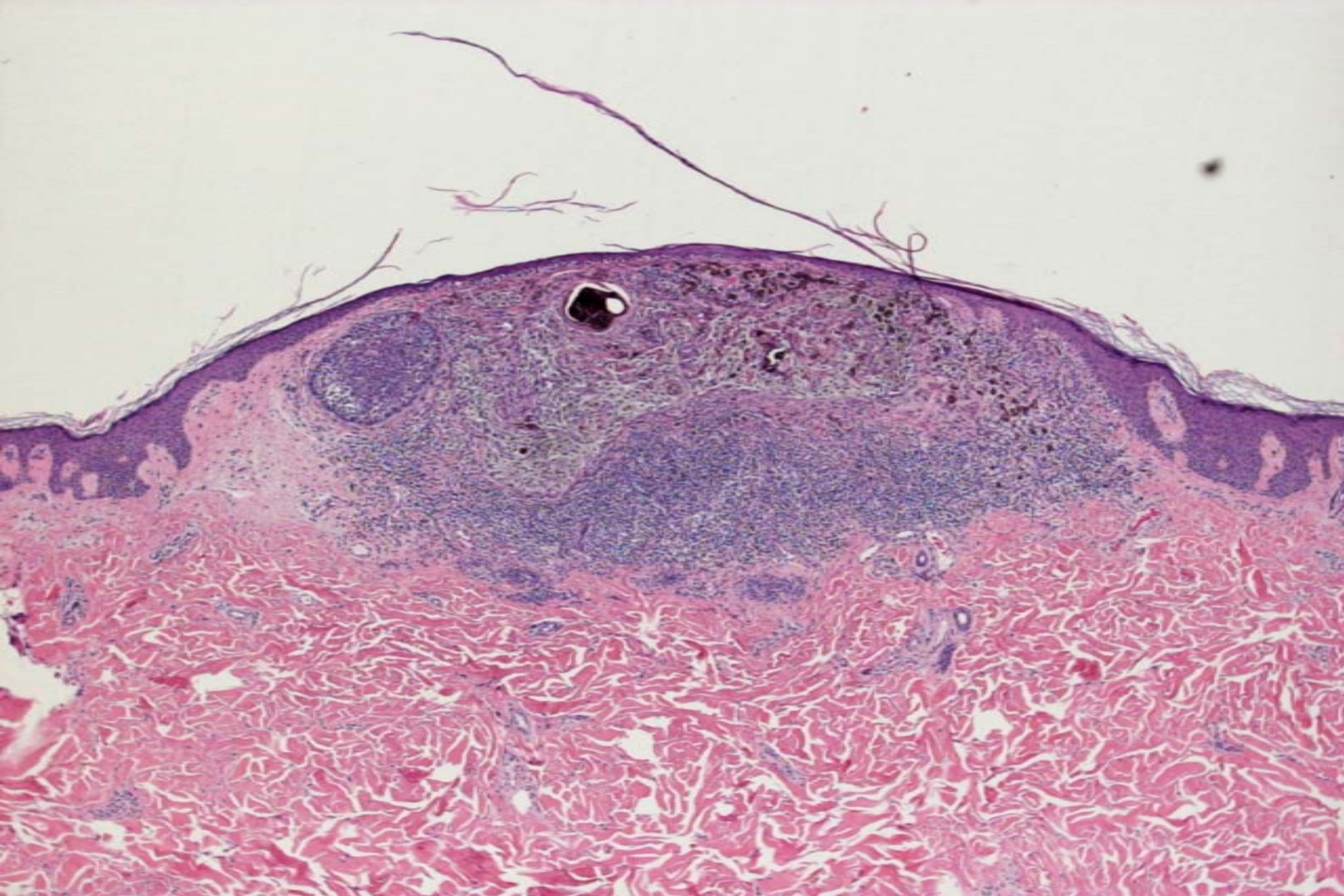


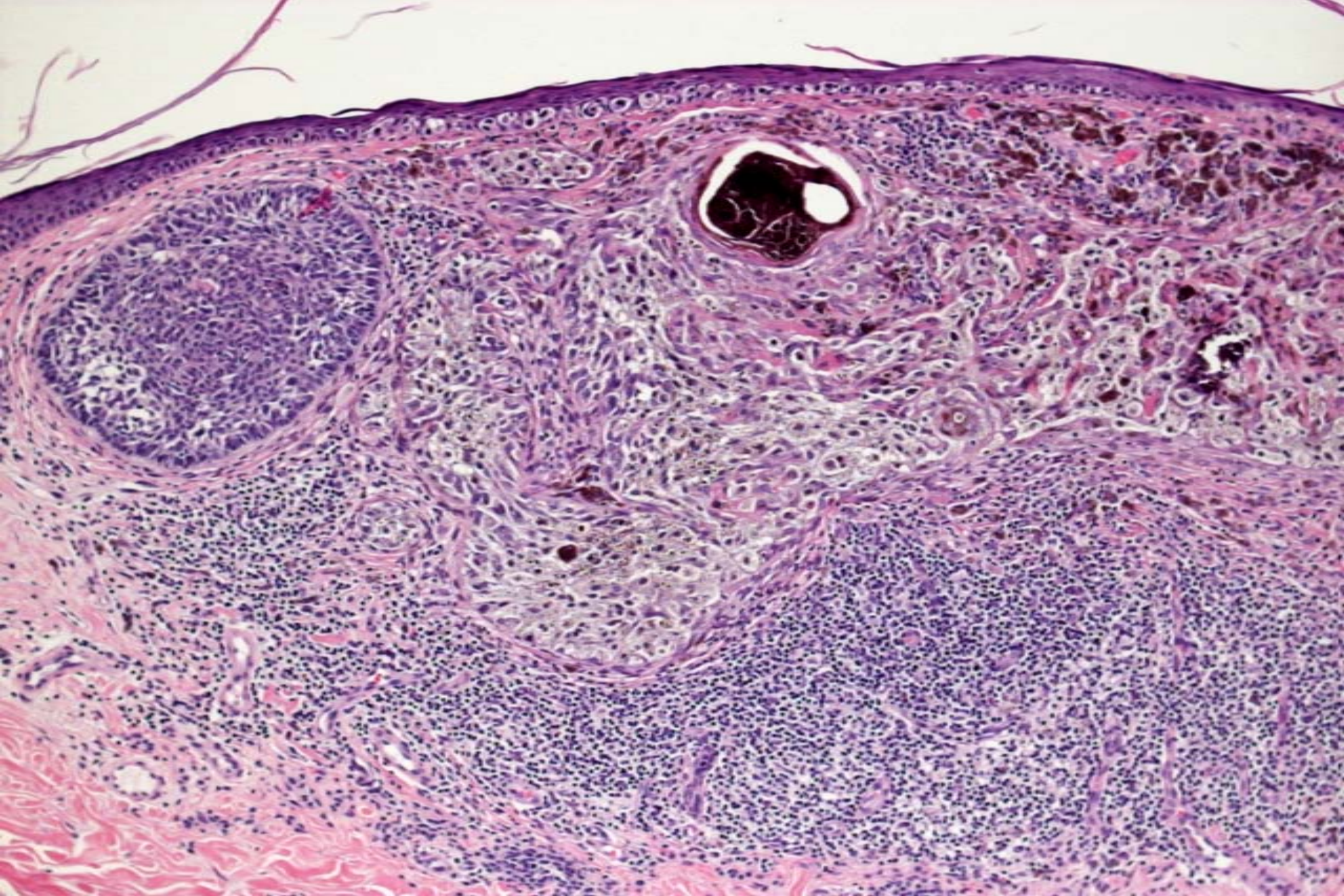


Case n. 6



1. Collision tumor (melanoma + BCC)
2. Melanoma
3. Combined nevus (Clark + Blue)
4. Congenital nevus





Case n. 6

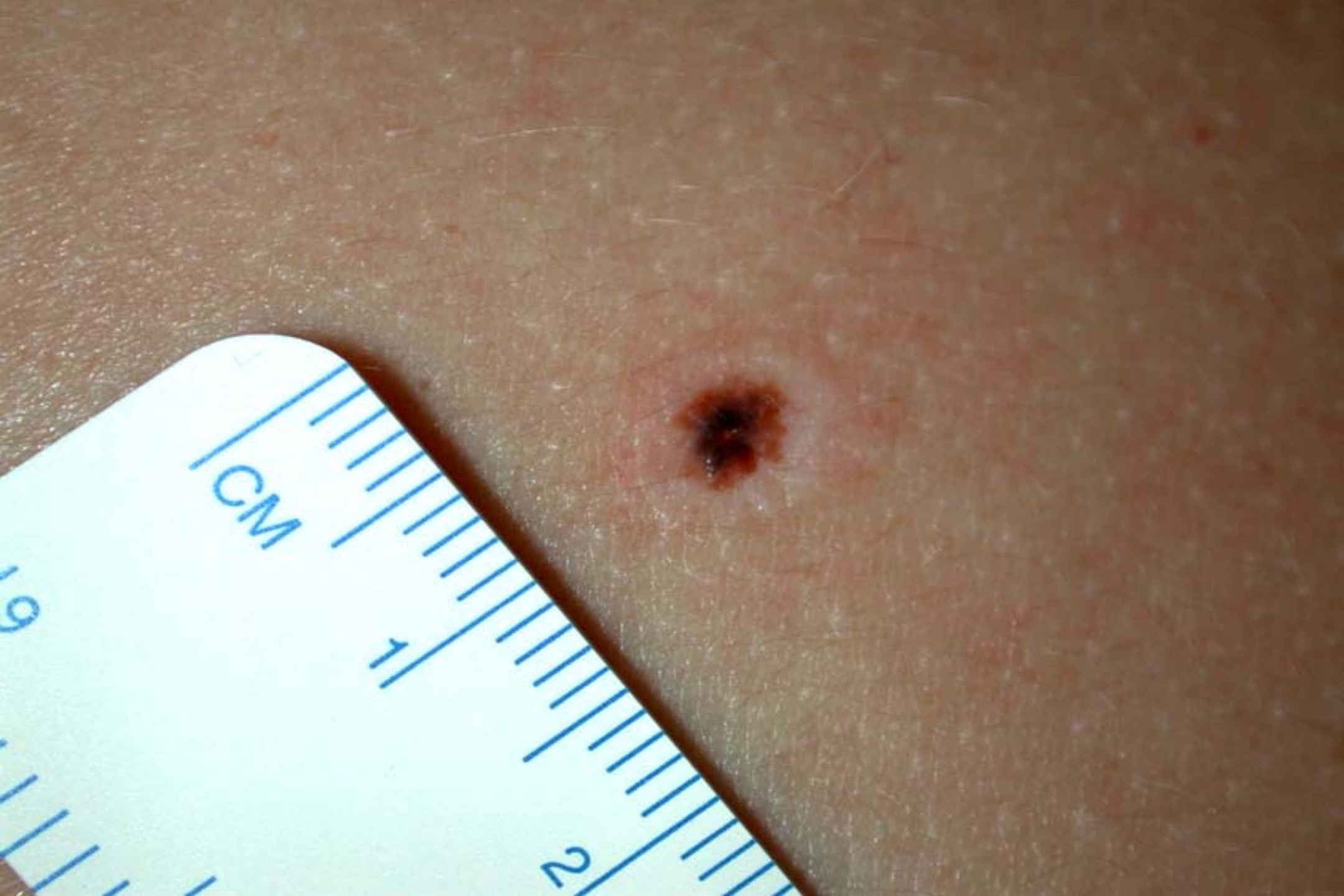

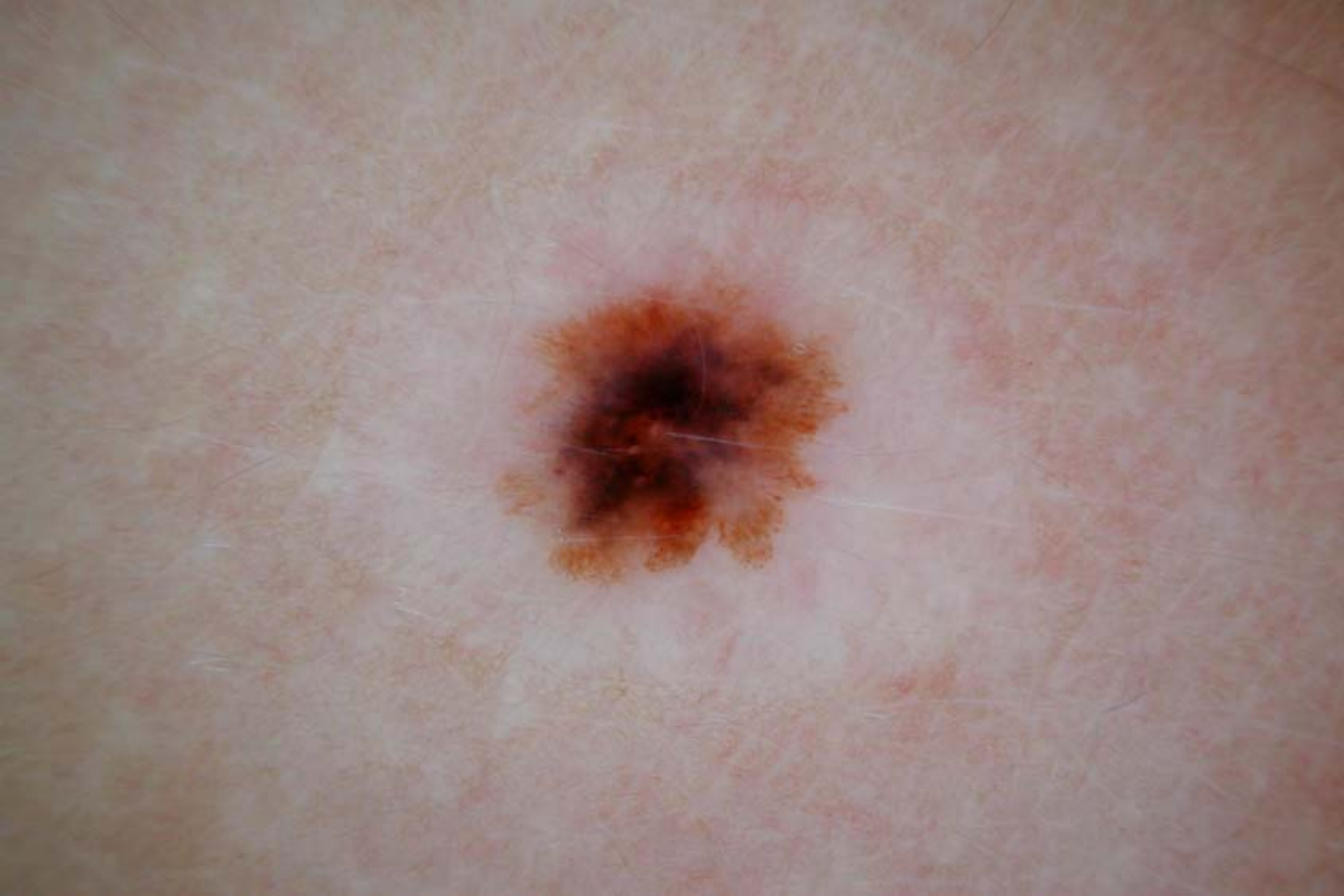1. Collision tumor (melanoma + BCC)
2. Melanoma
3. Combined nevus (Clark + Blue)
4. Congenital nevus

Case n. 7



- ***Age:*** 27-year-old
- ***Sex:*** female
- ***Location:*** back
- ***History:*** previous excision of a nevus

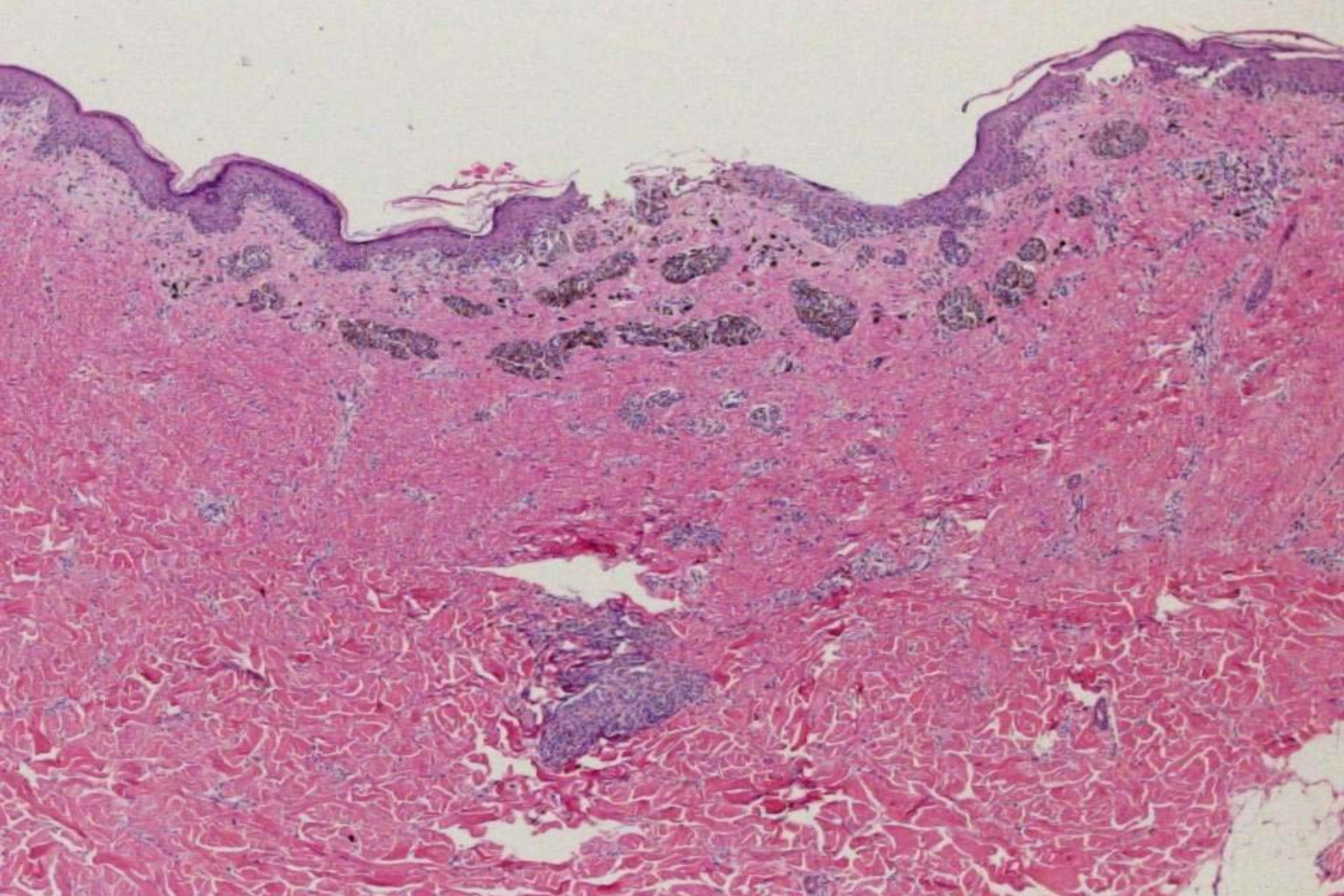


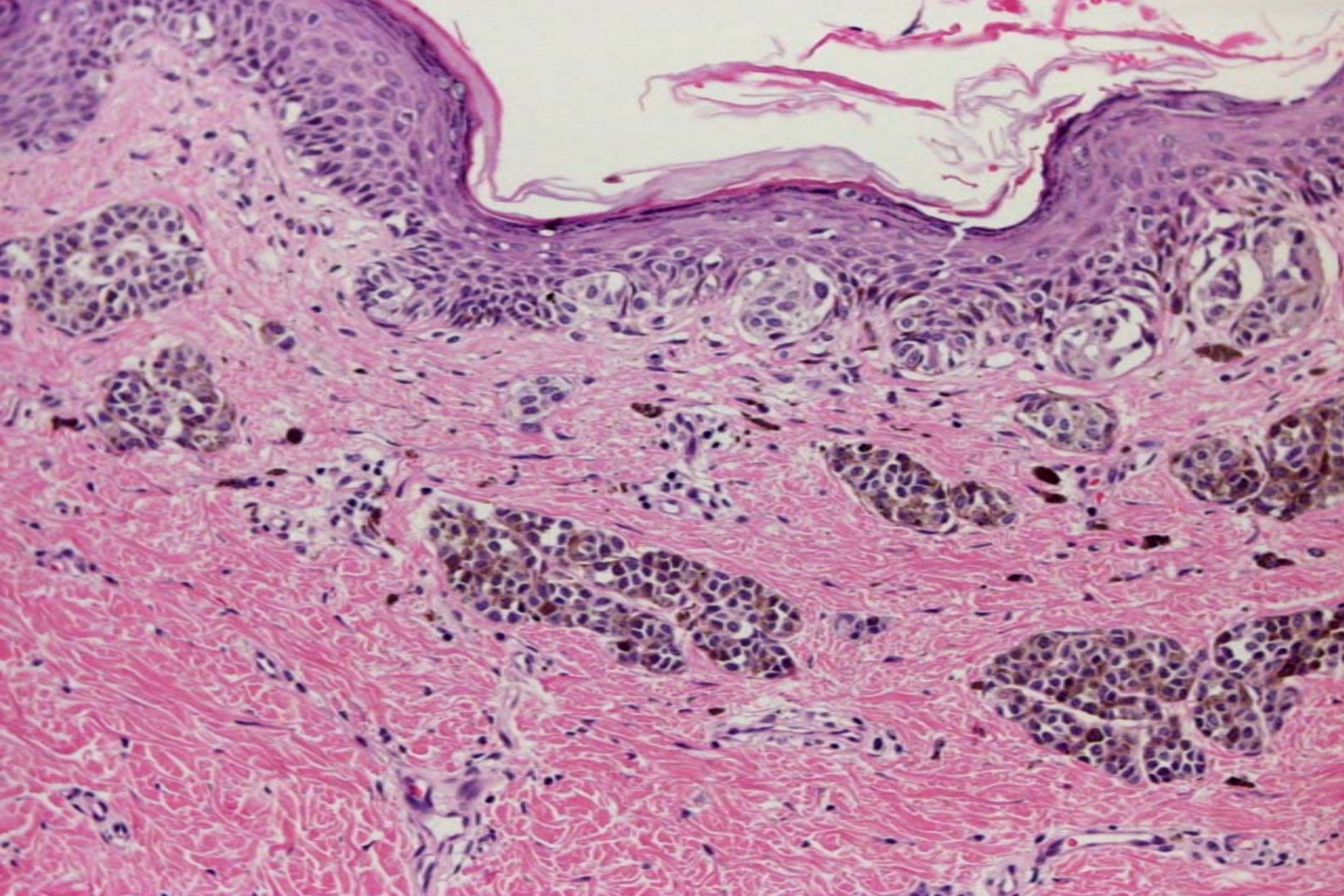


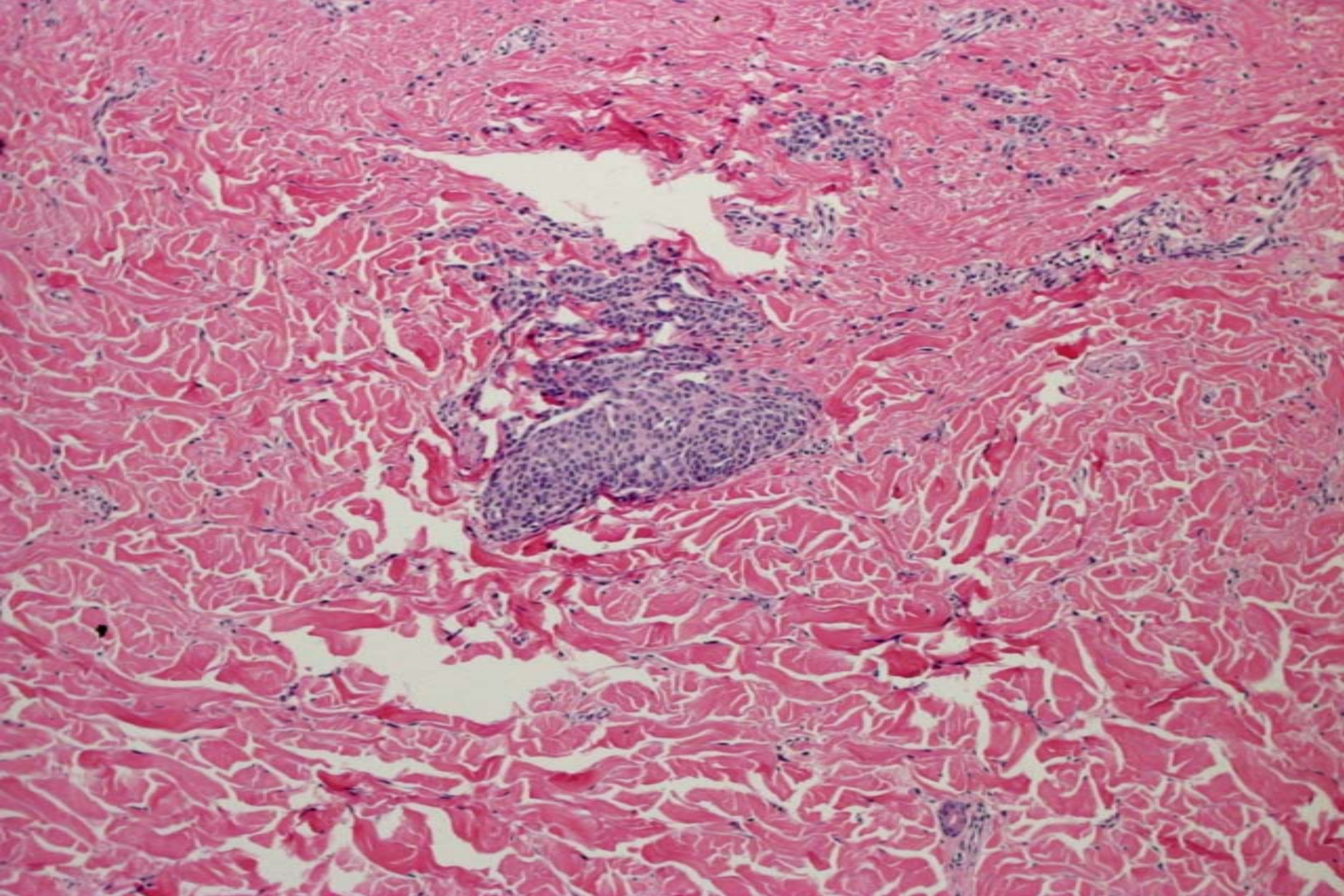
Case n. 7



1. Sutton nevus
2. Melanoma with regression
3. Recurrent nevus
4. Meyerson nevus







Case n. 7



1. Sutton nevus
2. Melanoma with regression
3. Recurrent nevus
4. Meyerson nevus

