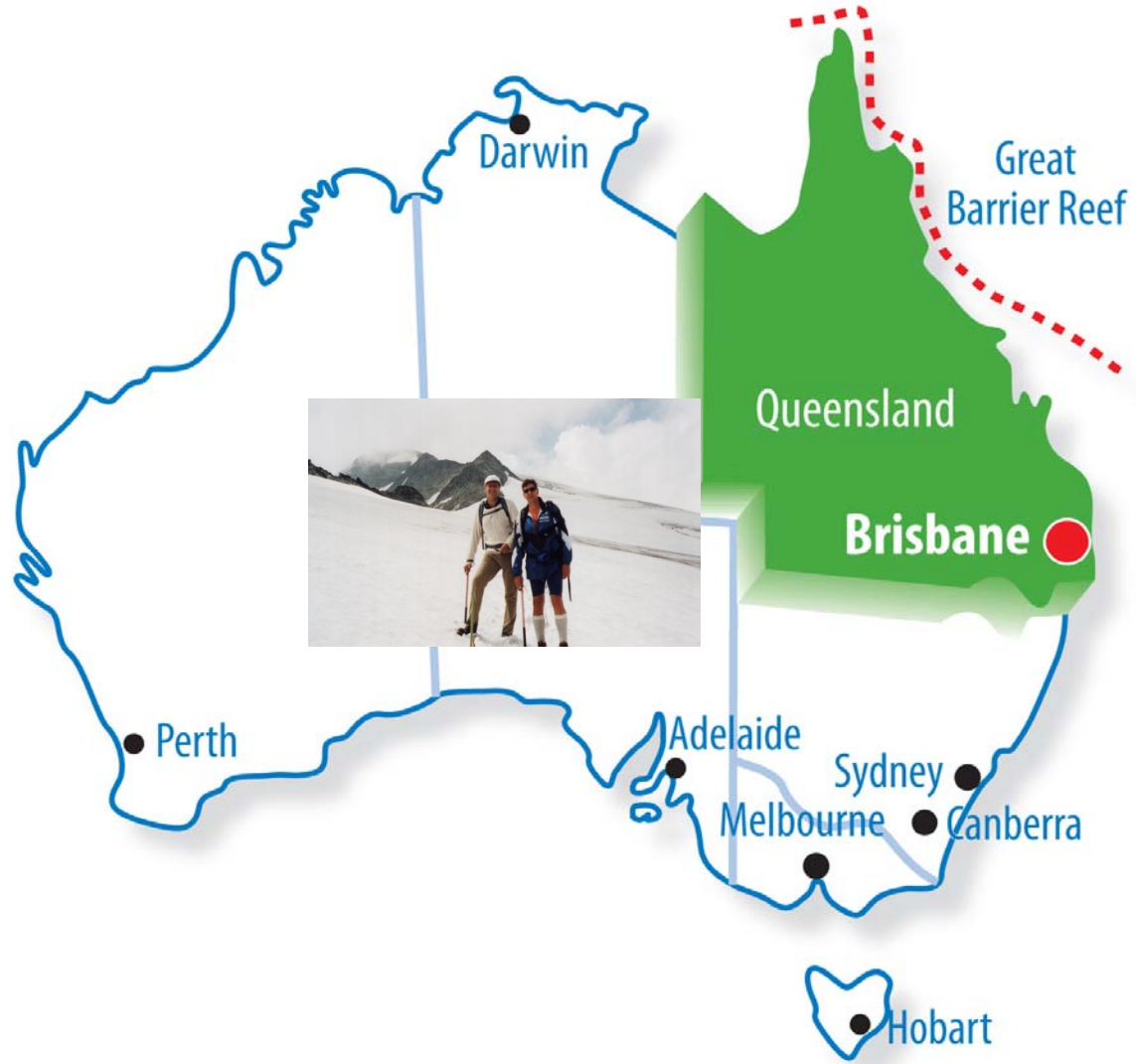

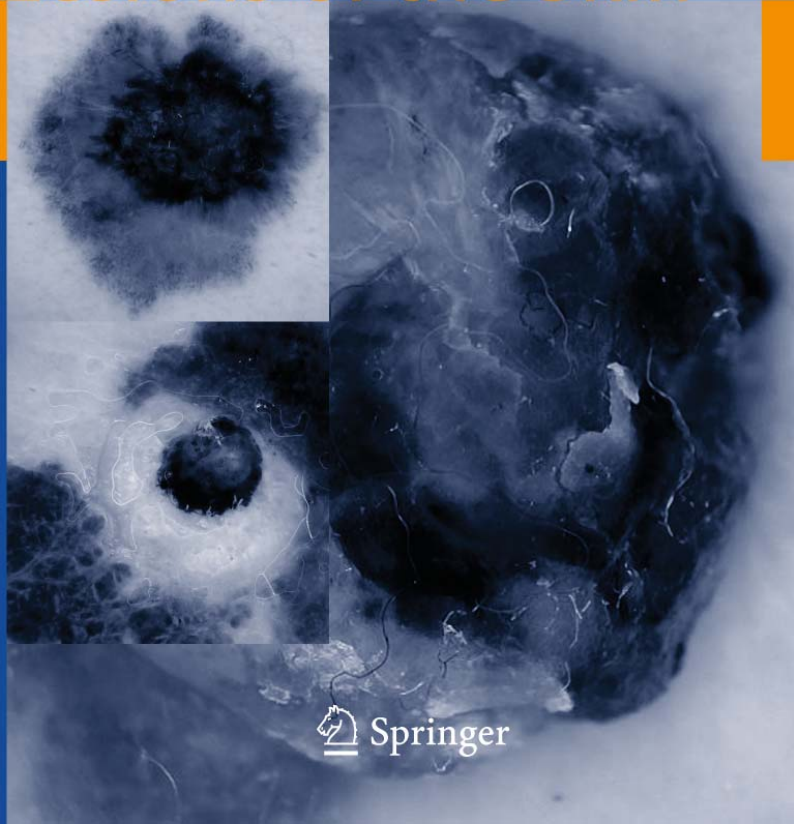Disclosure of Conflict of Interest


- Co-founder of e-derm-consult GmbH, a spin-off company of the Medical University of Graz, Graz, Austria, with special emphasis on teledermatology
- Share-holder of MoleMap by Dermatologists, Australia Pty Ltd
- Medical Advisory Board of Scansol Ltd, Skin Cancer Solutions, UK

Color Atlas of Melanocytic Lesions of the Skin

H. P. Soyer · G. Argenziano
R. Hofmann-Wellenhof
R. Johr *Editors*



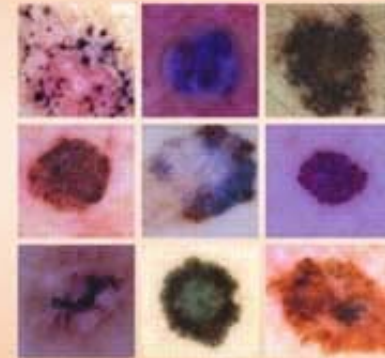
 Springer



DERMOSCOPY
The Essentials

THE ENCYCLOPEDIA OF VISUAL MEDICINE SERIES

Atlas of
DERMOSCOPY



Edited by
Ashfaq A. Marghoob MD
Ralph P. Brannon MD and
Alfred W. Kopf MD (derm)



Forschung

Forschungsprofil
Forschungseinrichtungen
Forschungsmanagement
& Forschungsförderung
Kooperation

Studium

Studienangebot
Internationales
Weiterbildung
Qualitätssicherung
Zuständige Stellen

Gesundheit

Organisation
Gesundheitsuniversität
Besondere Aktivitäten
Aktuelles

Dermoscopy :: International Dermoscopy Diploma (e-learning course)

International Short Course on Dermoscopy

International Dermoscopy Diploma (e-learning course)

- > General Information
- > Program
- > Faculty
- > Booking For The Next Course 2009/2010
- > Participants' Comments
- > Participants Area

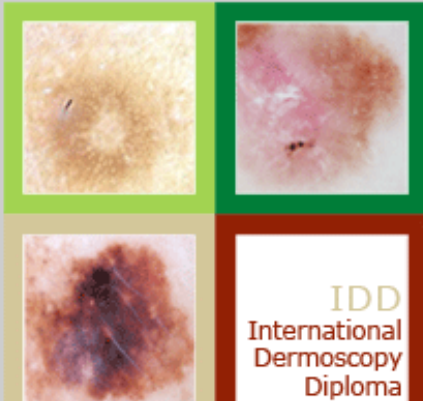
IDD INTERNATIONAL DERMOSCOPY DIPLOMA

an e-learning course

October 2008 - June 2009

This unique e-learning course is composed of 10 different learning modules covering all relevant fields of dermoscopy.

➤ **Participants Area**



Iris Zalaudek

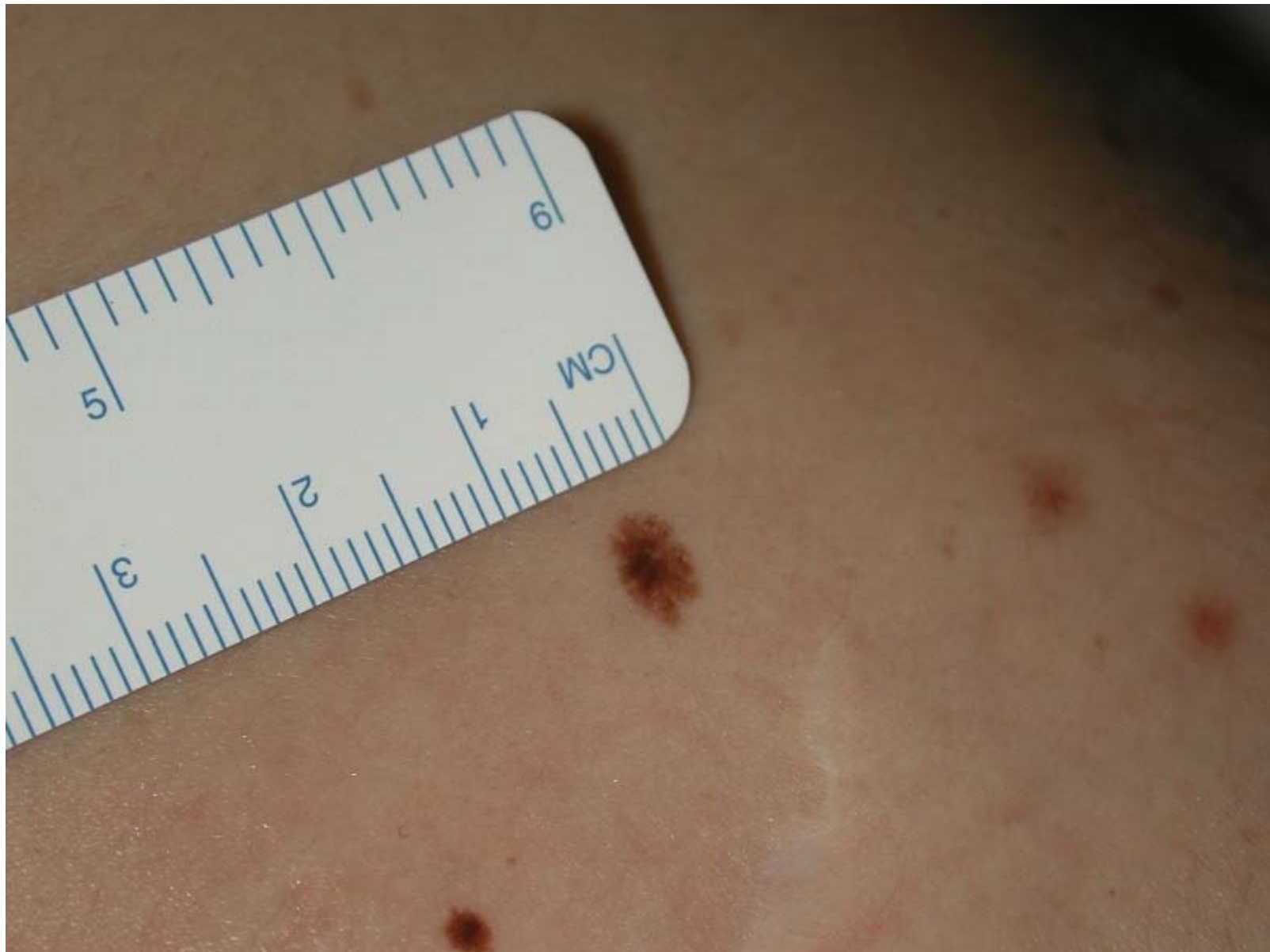Giuseppe Argenziano

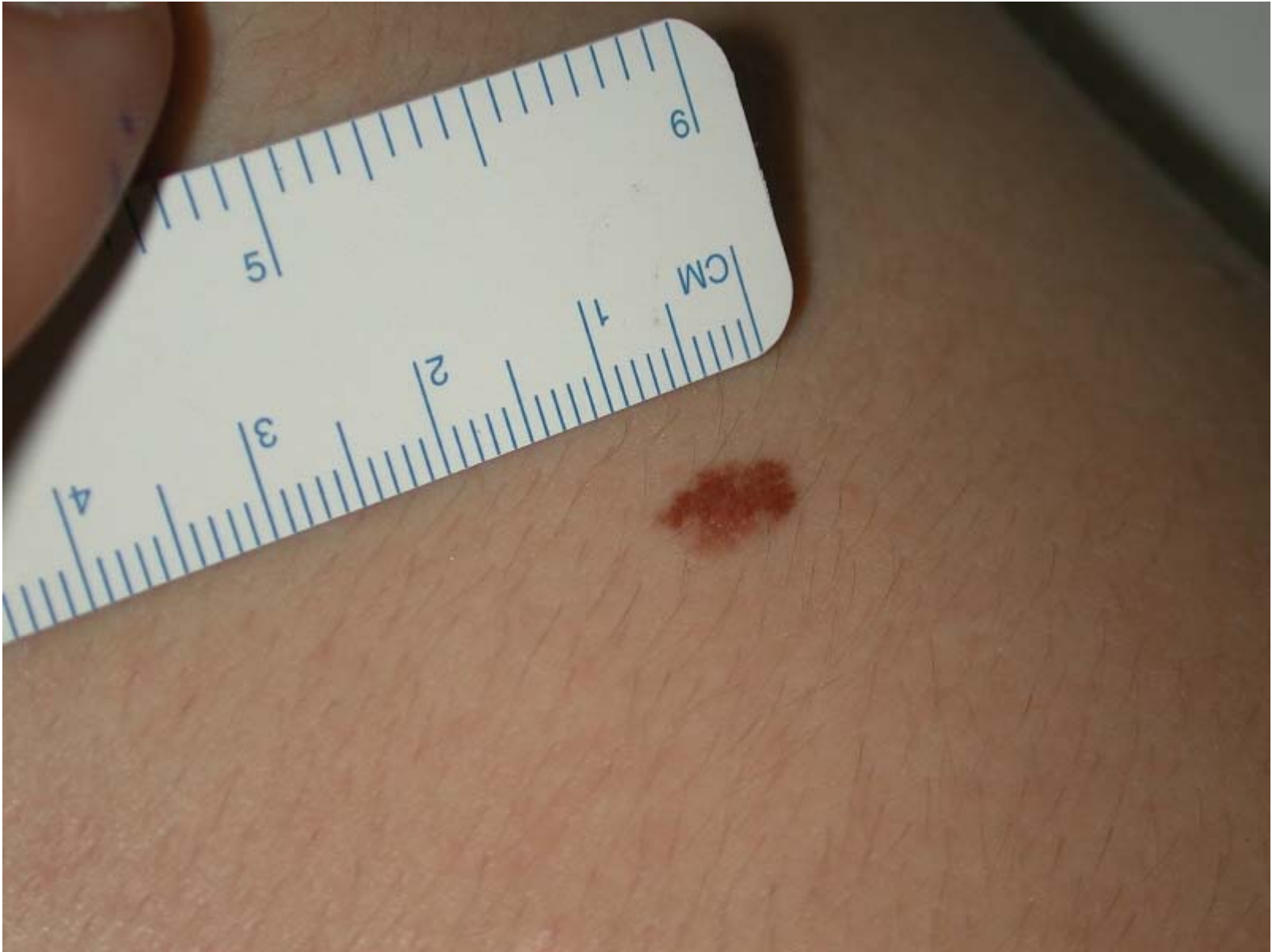Rainer Hofmann-Wellenhof

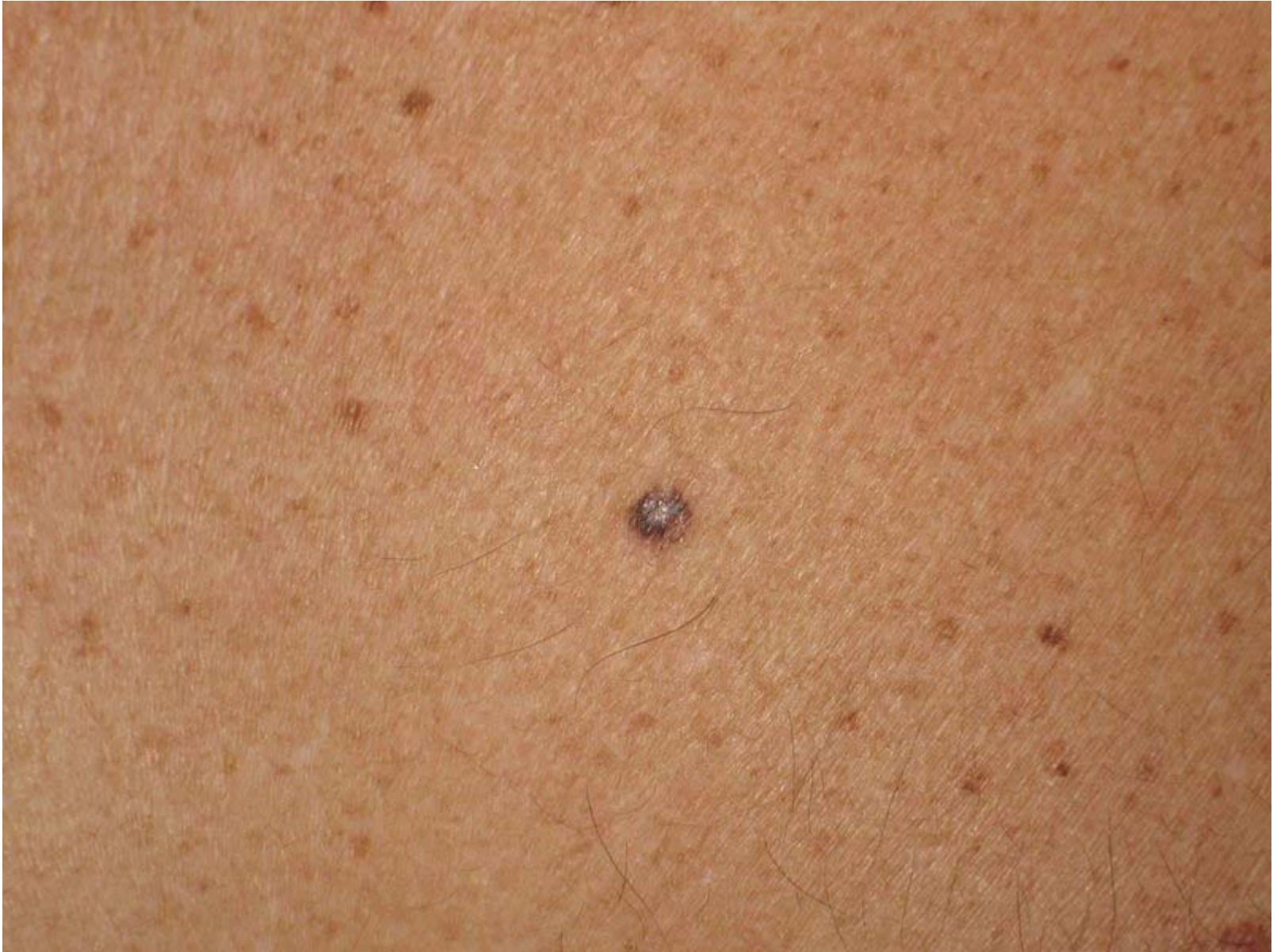H. Peter Soyer

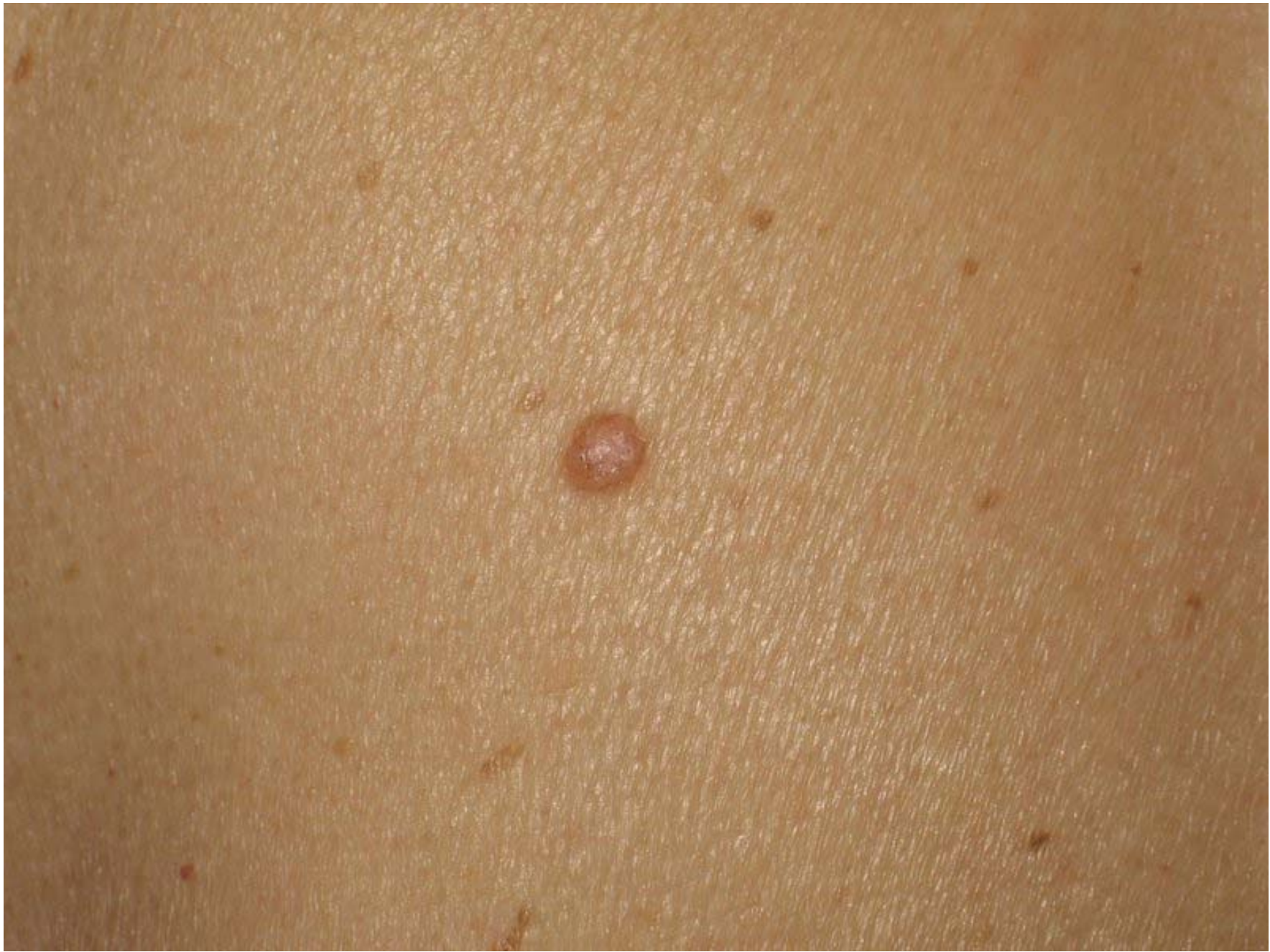Management

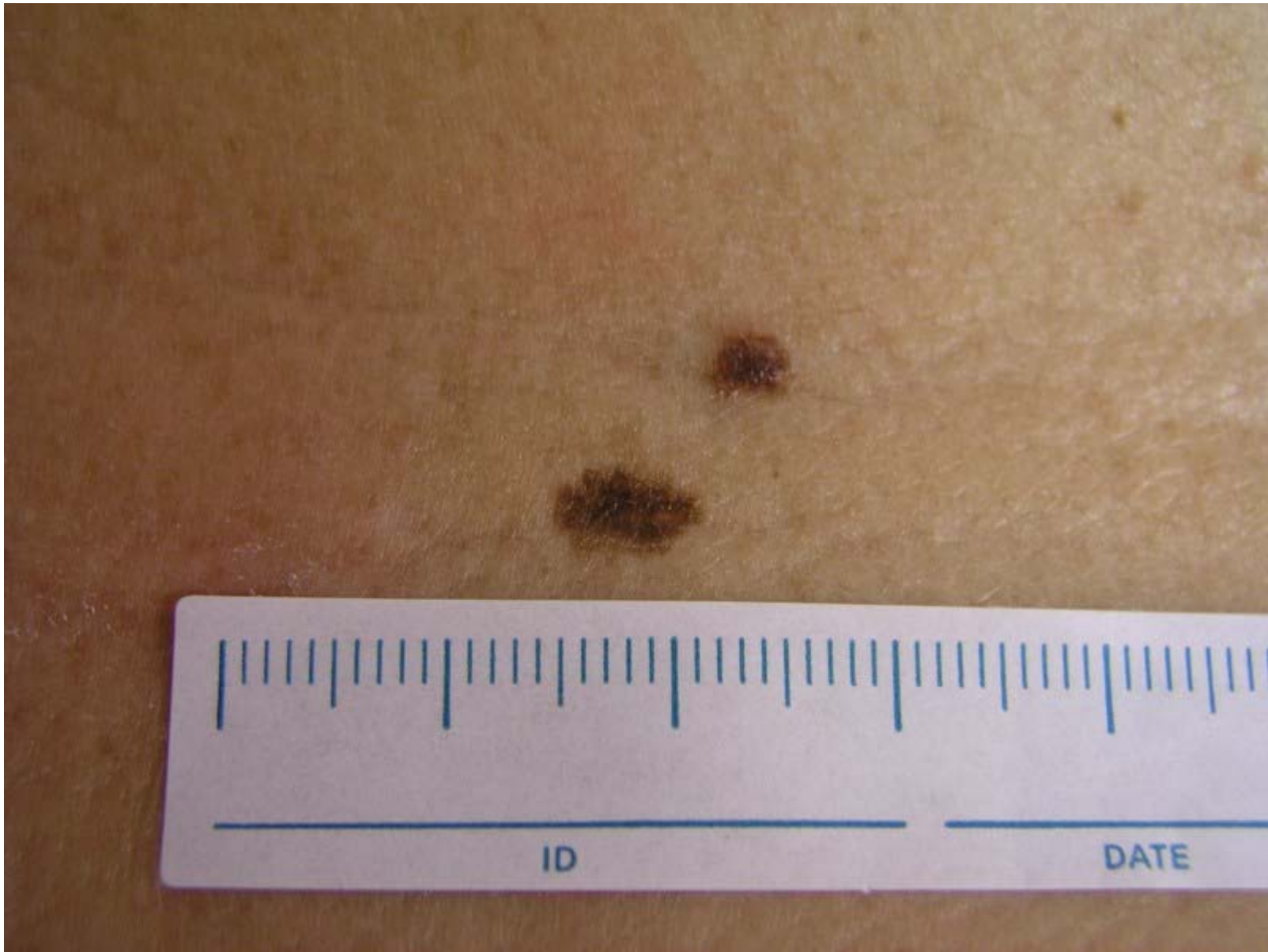
- How many lesions do you excise with your naked eye?

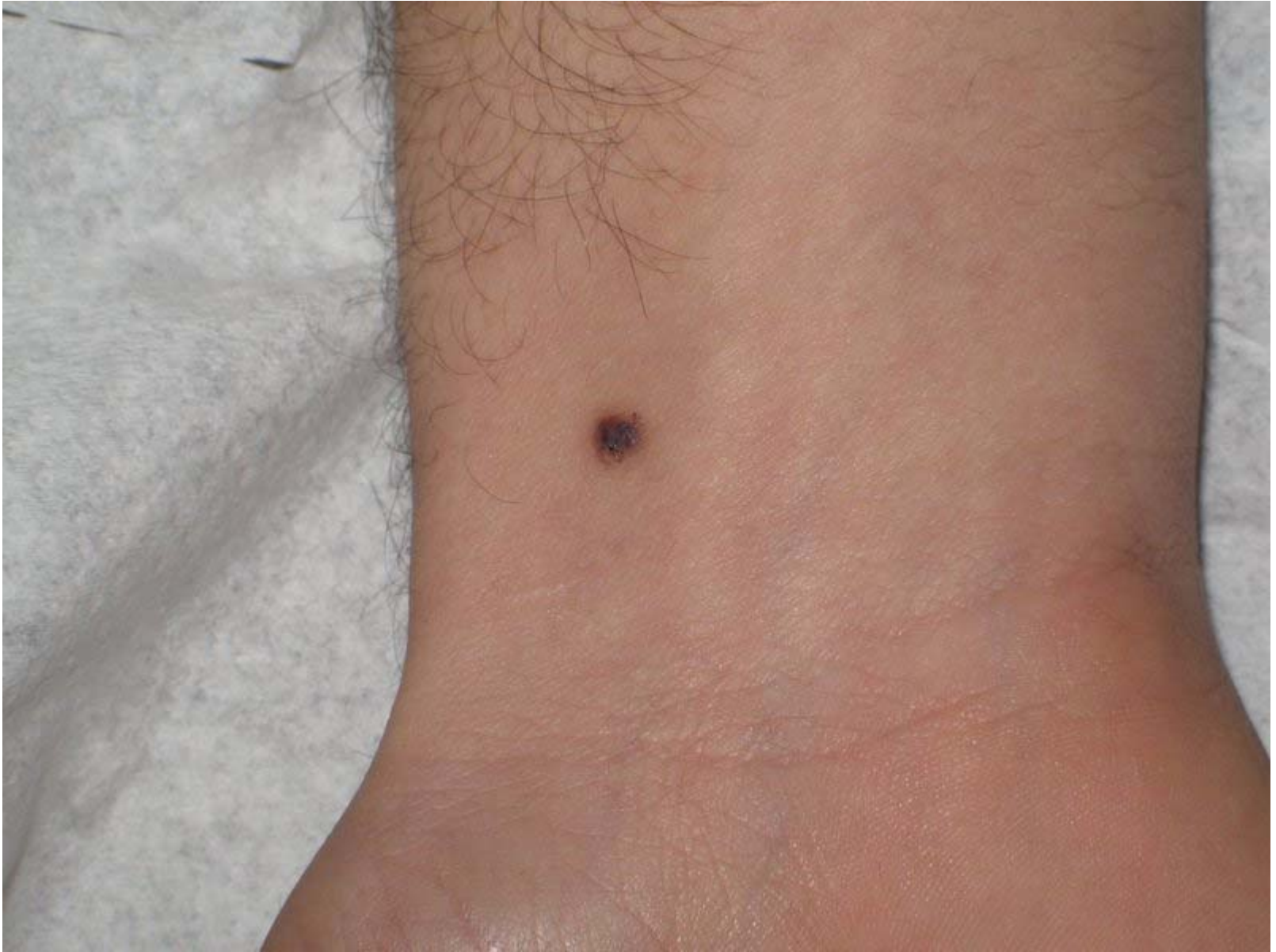


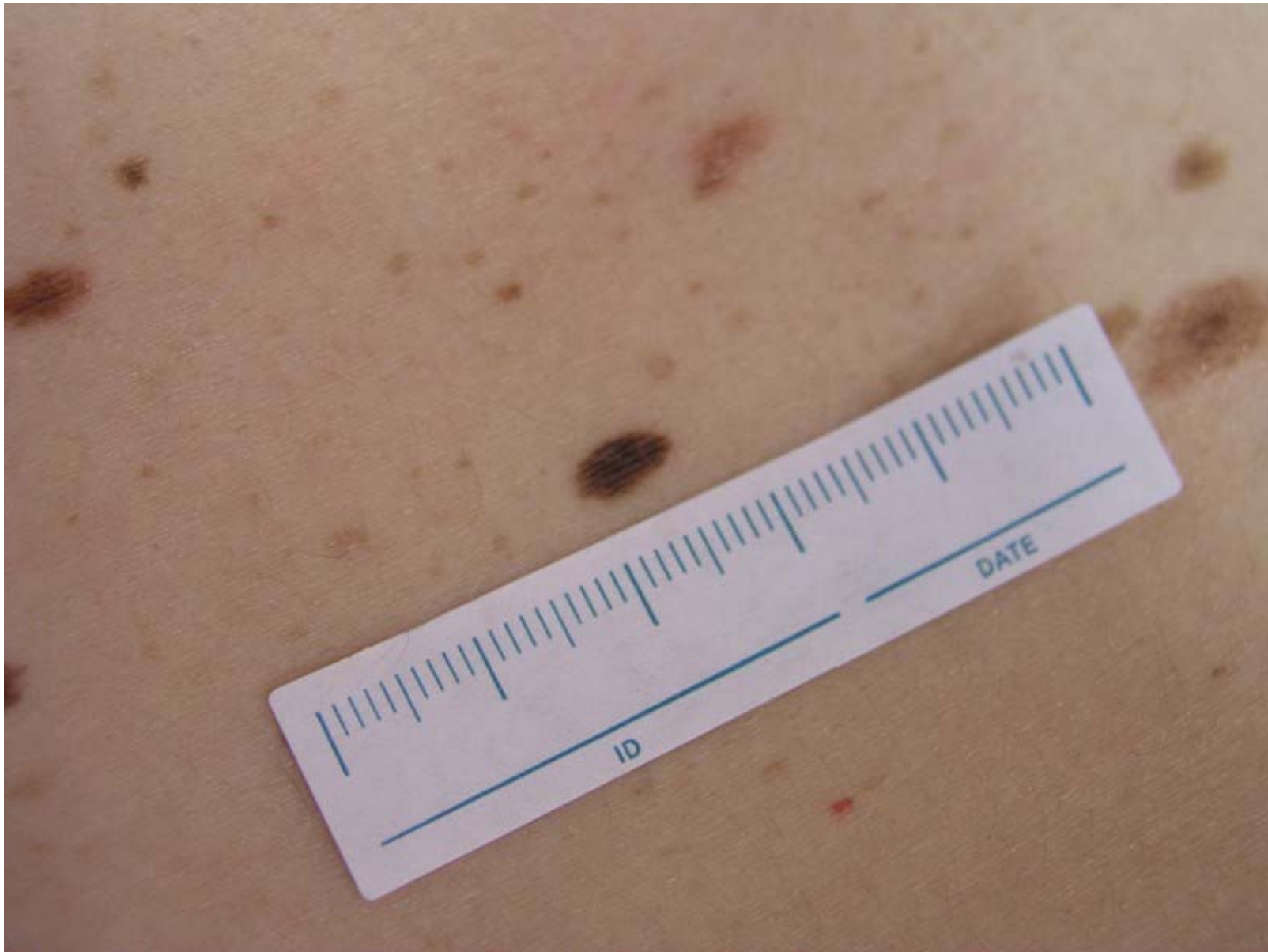


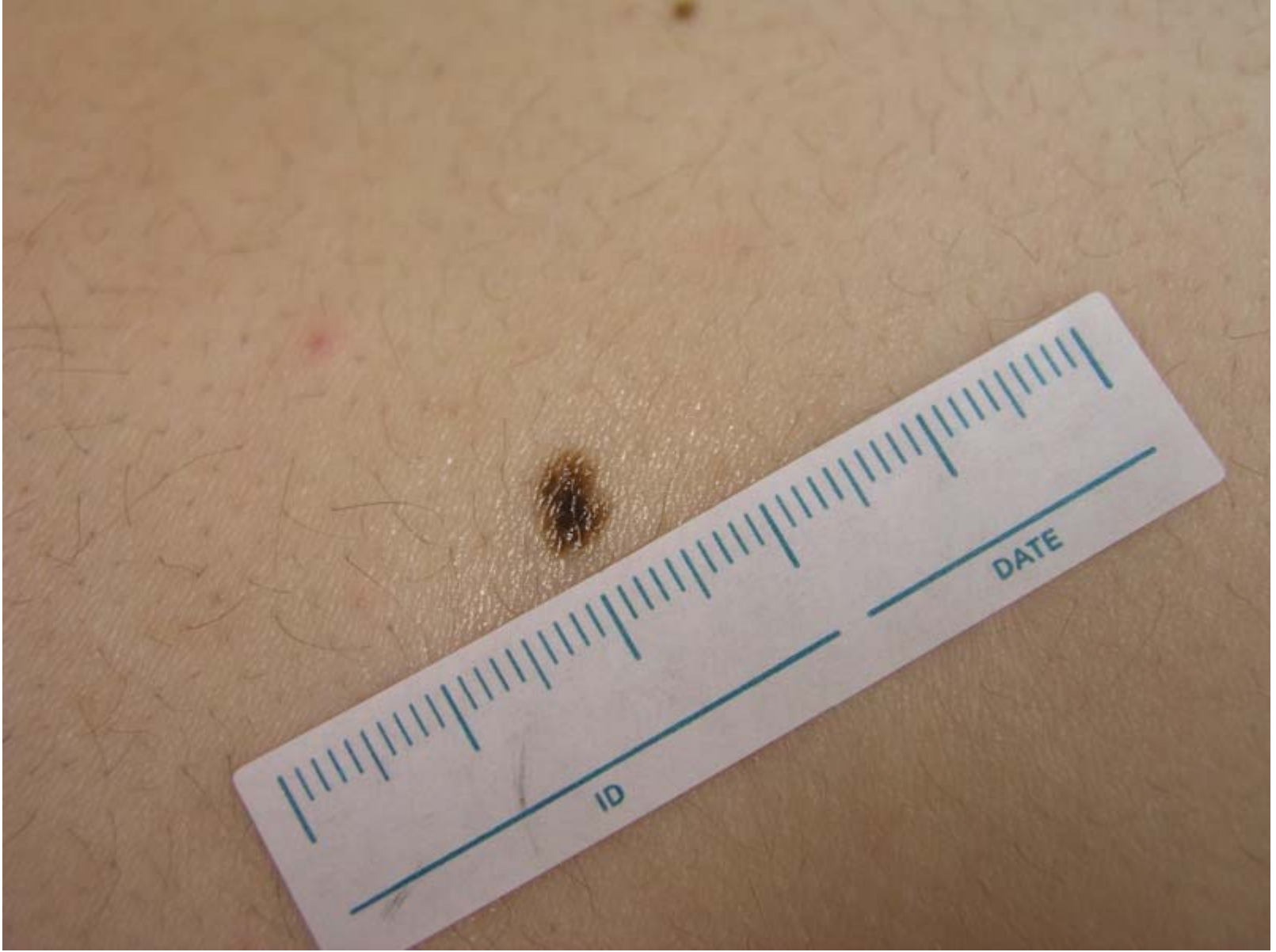


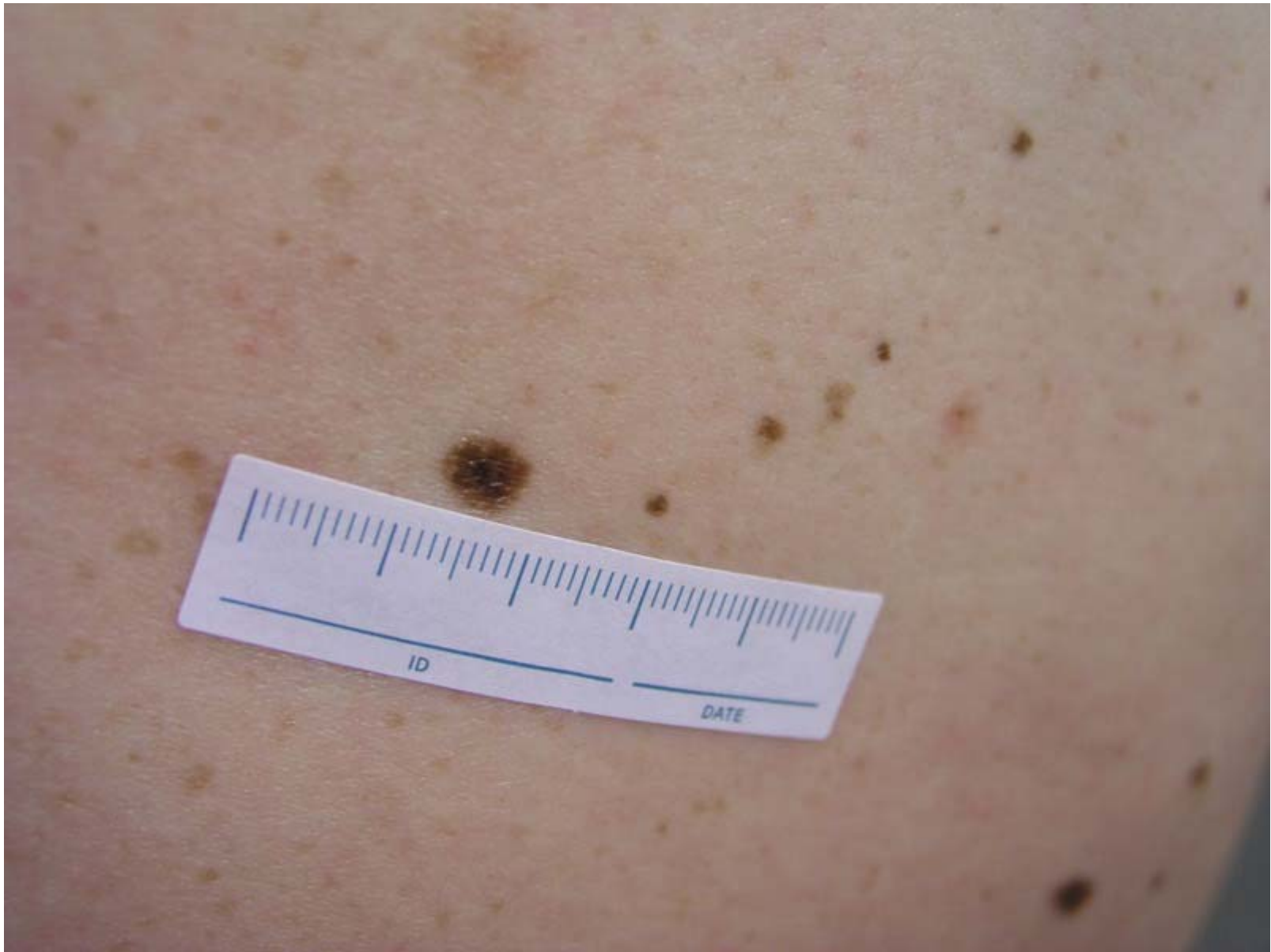


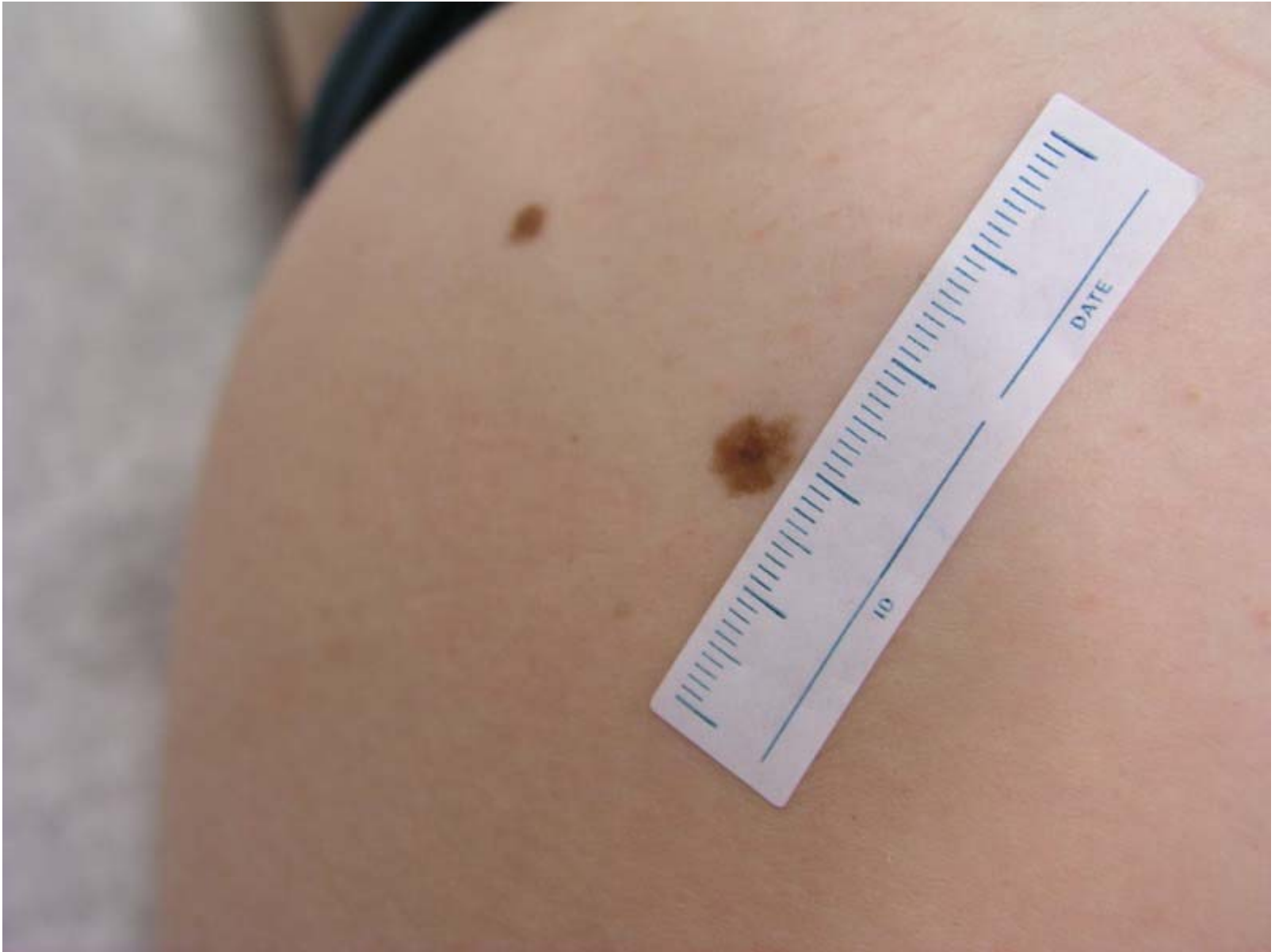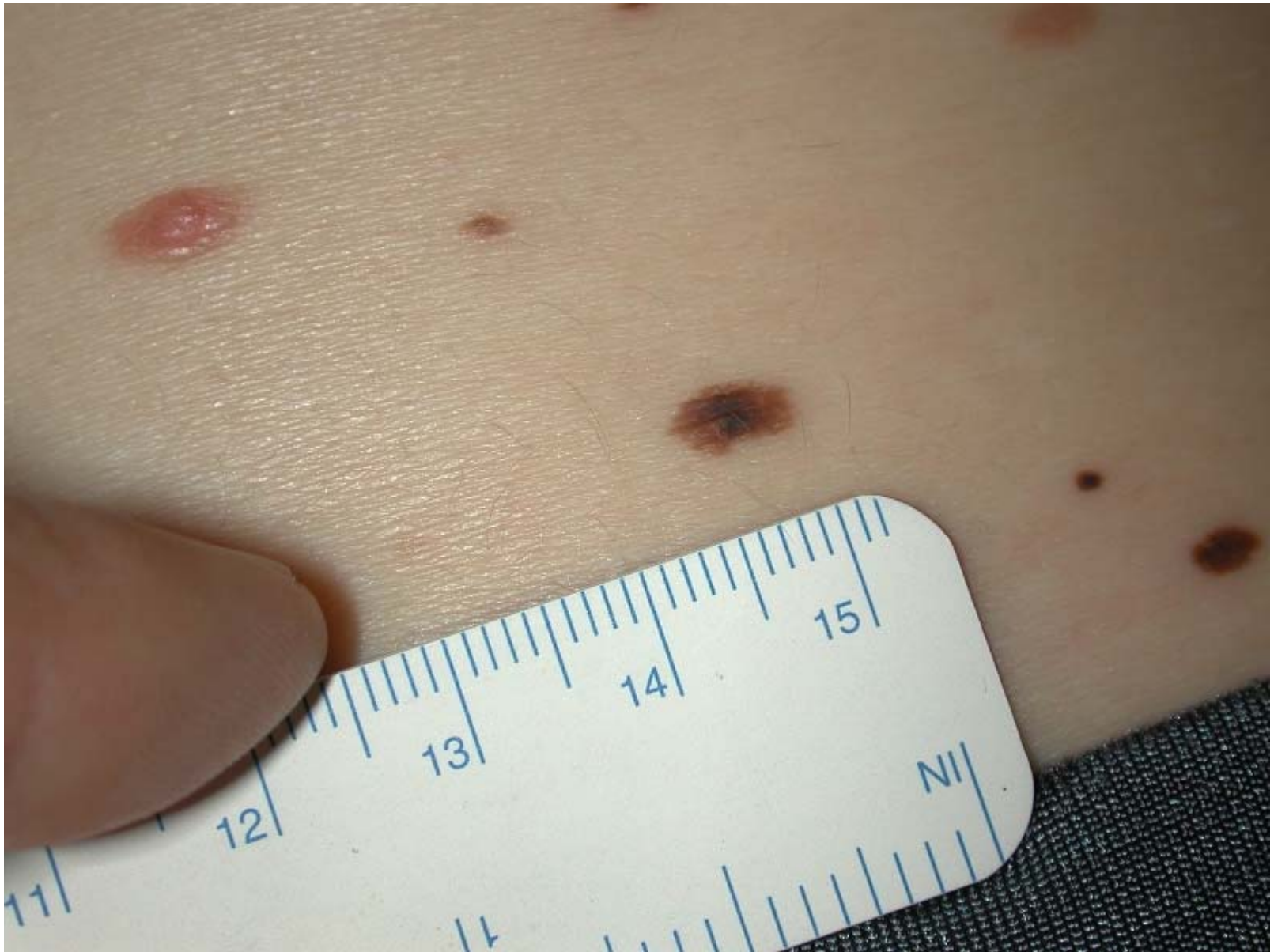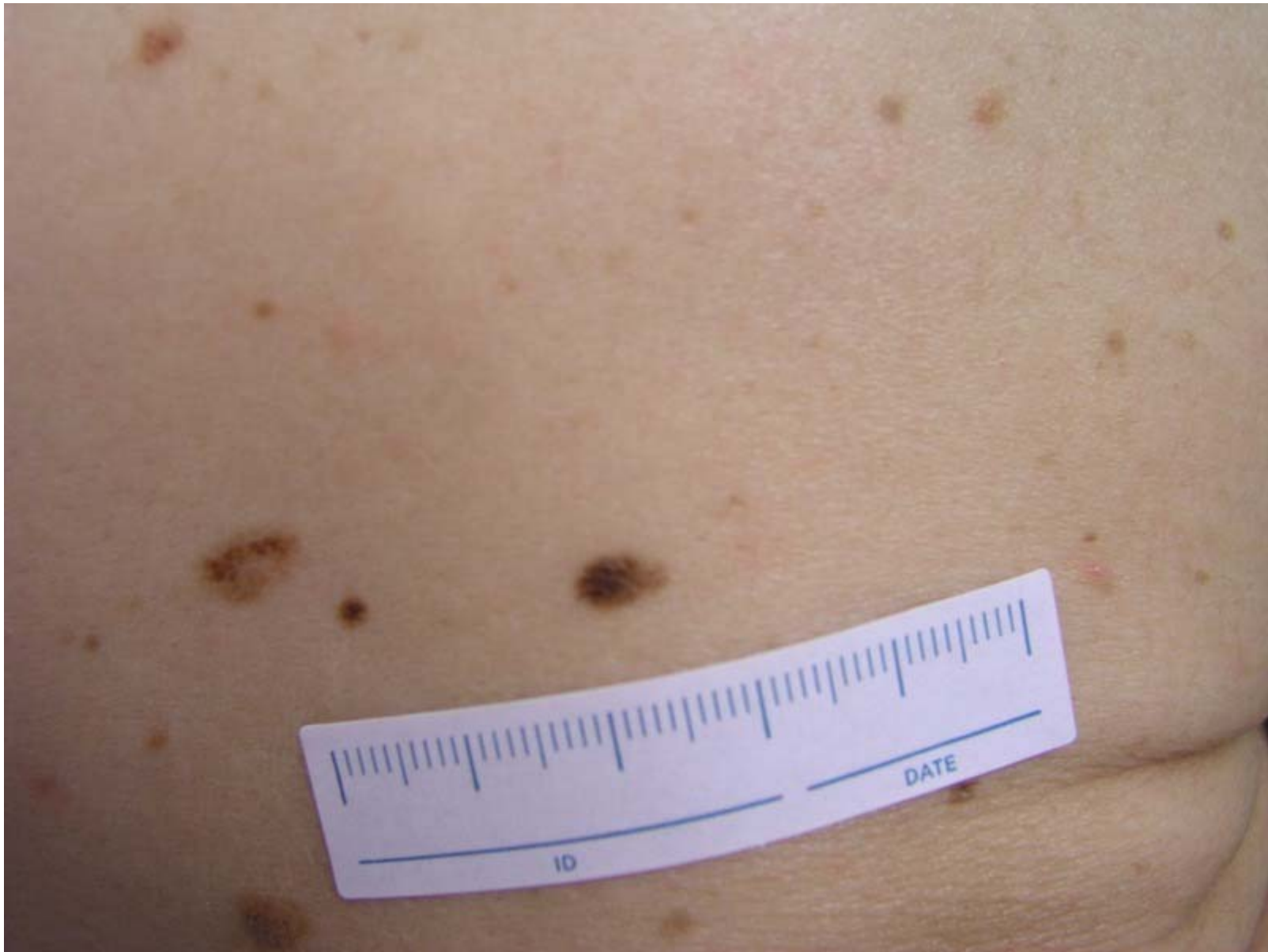








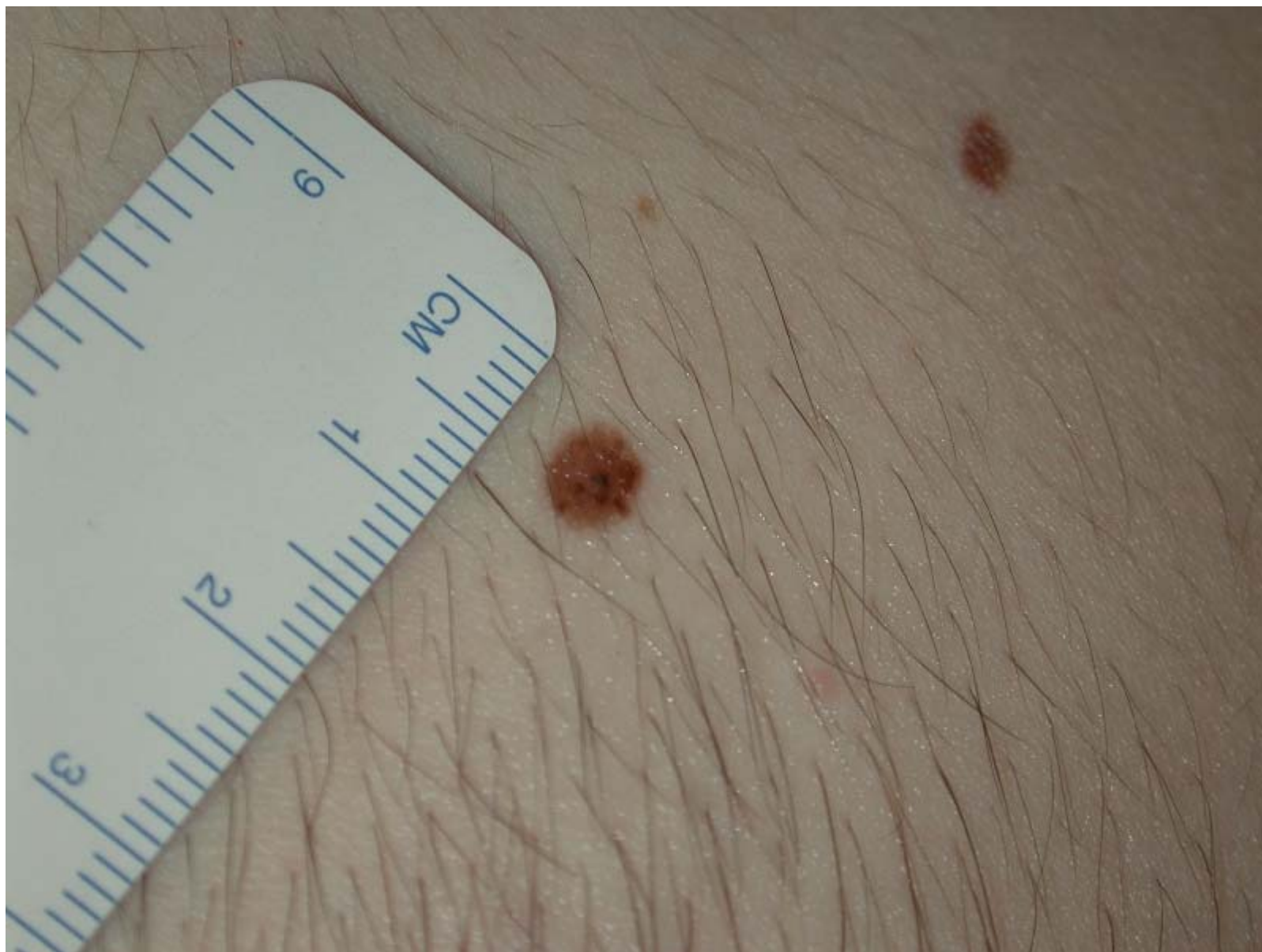


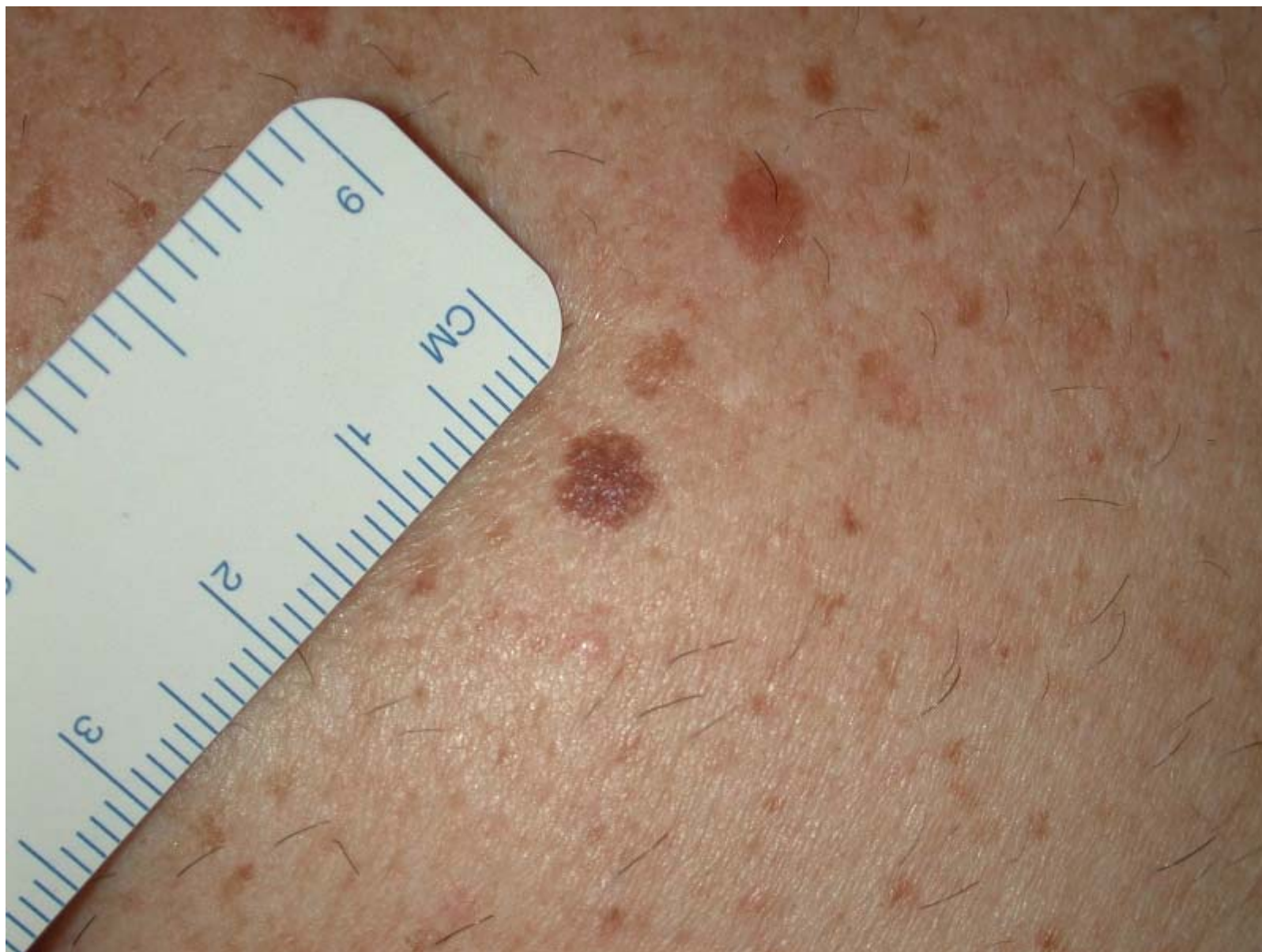


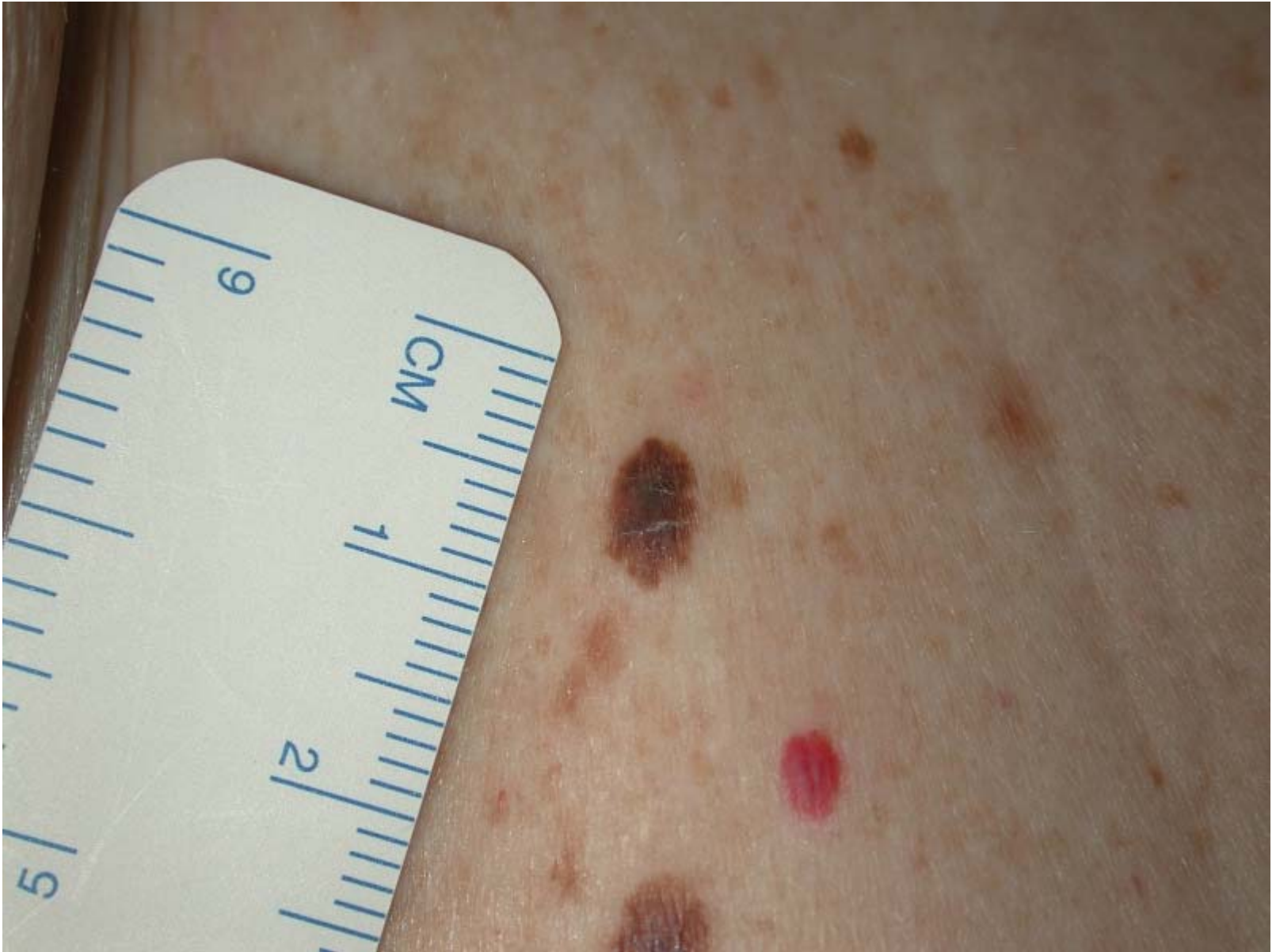



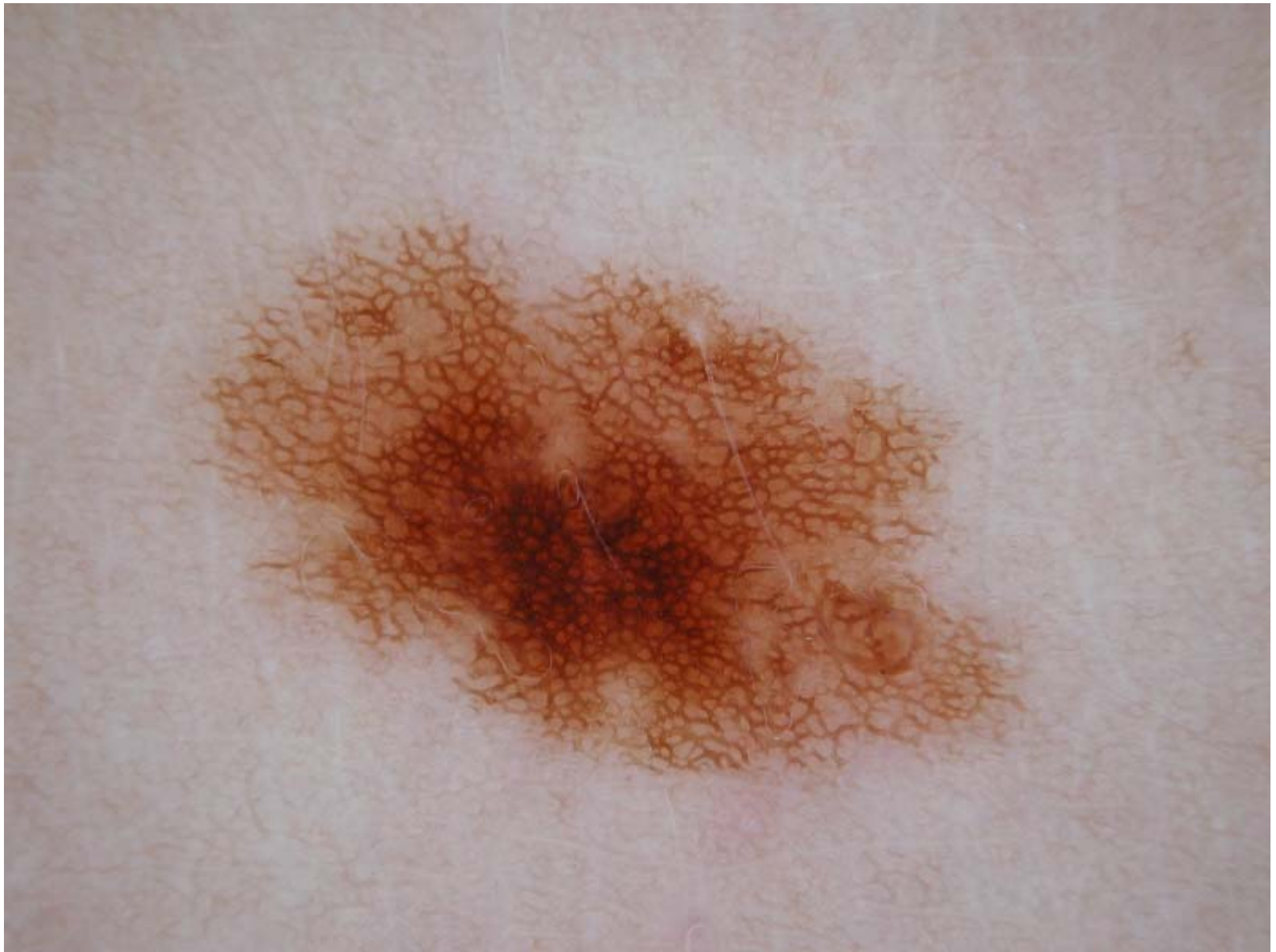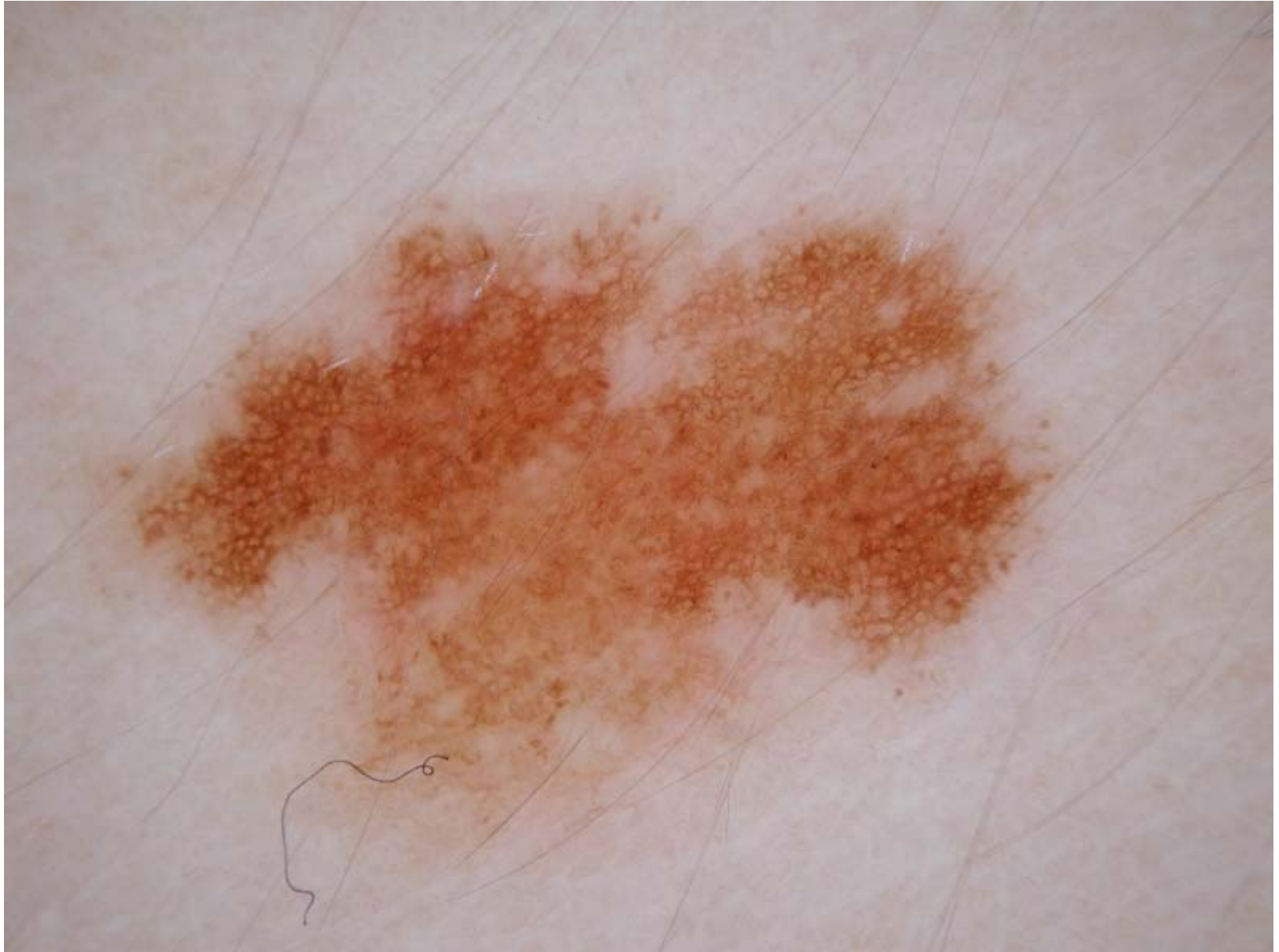Management

- How many lesions do you excise with your naked eye?
- How many lesions do you excise with dermoscopy?

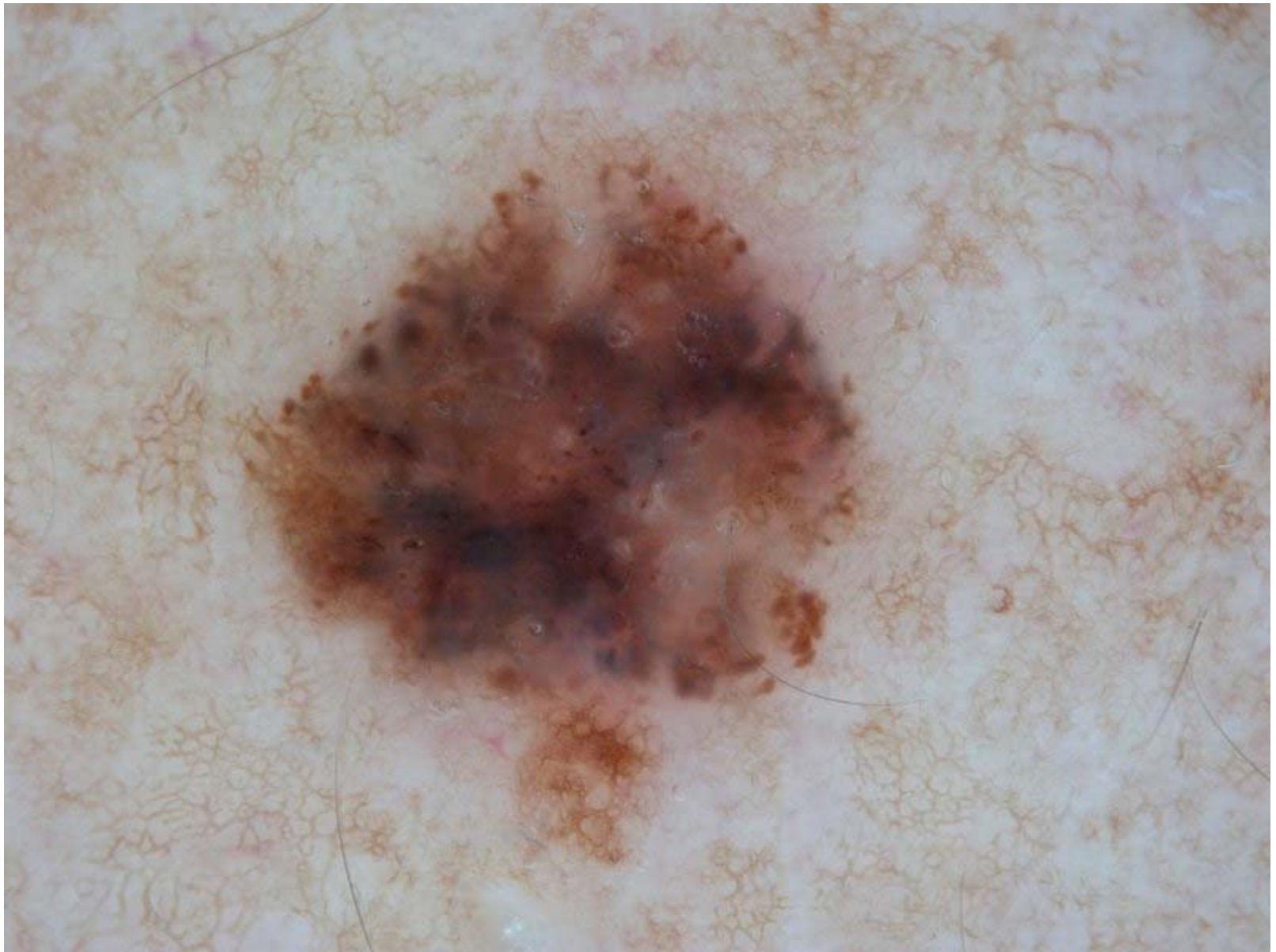




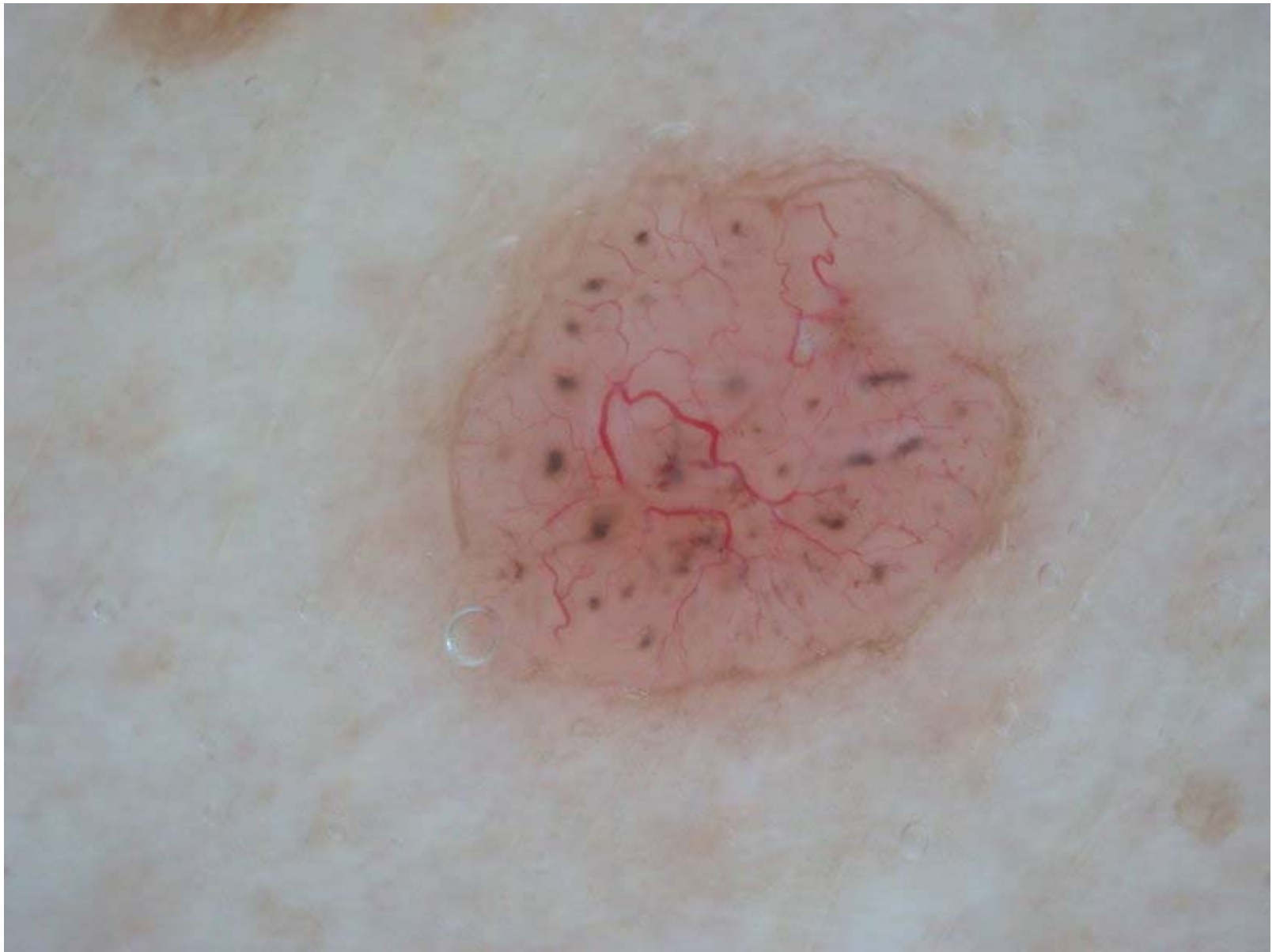


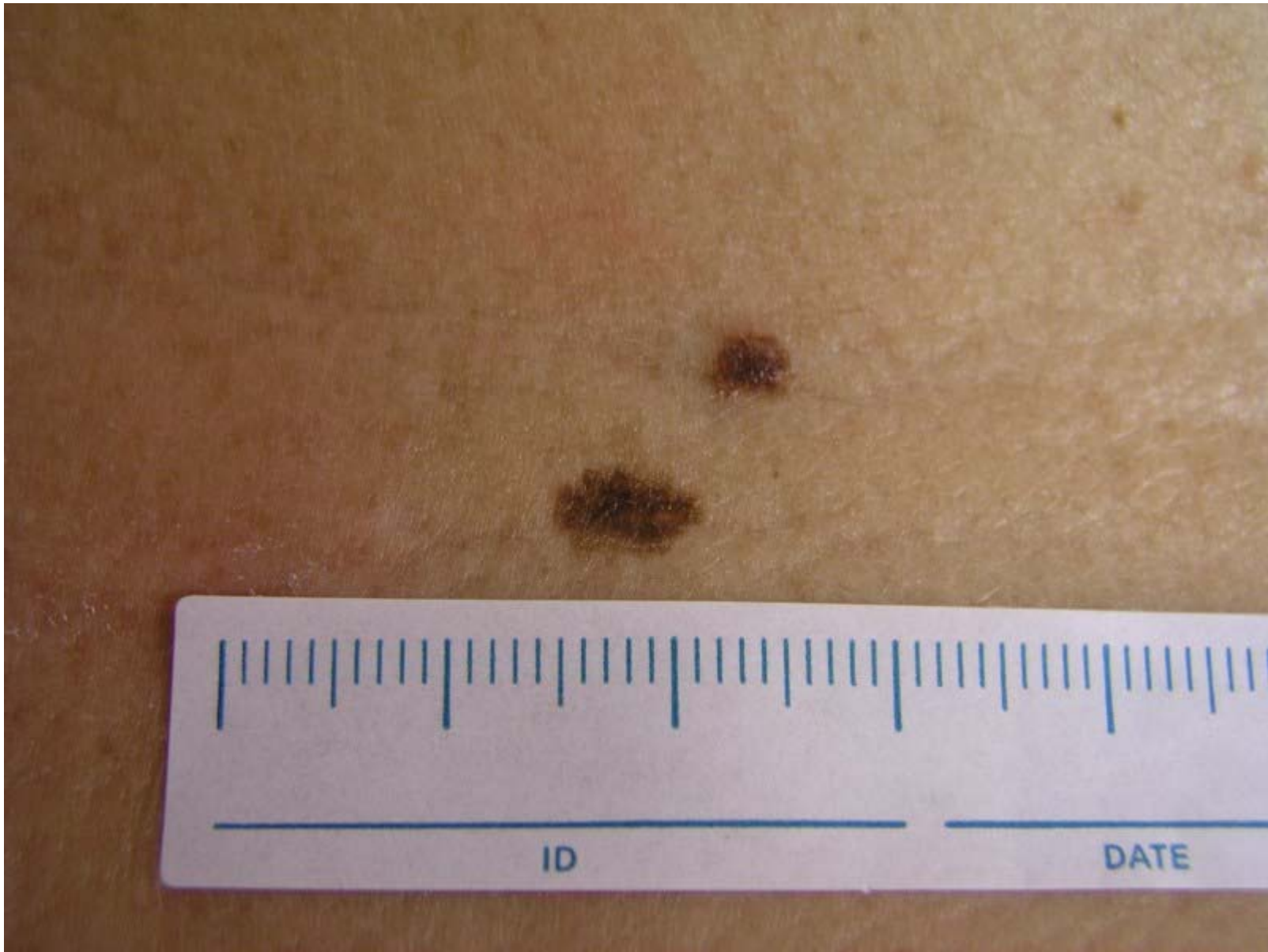


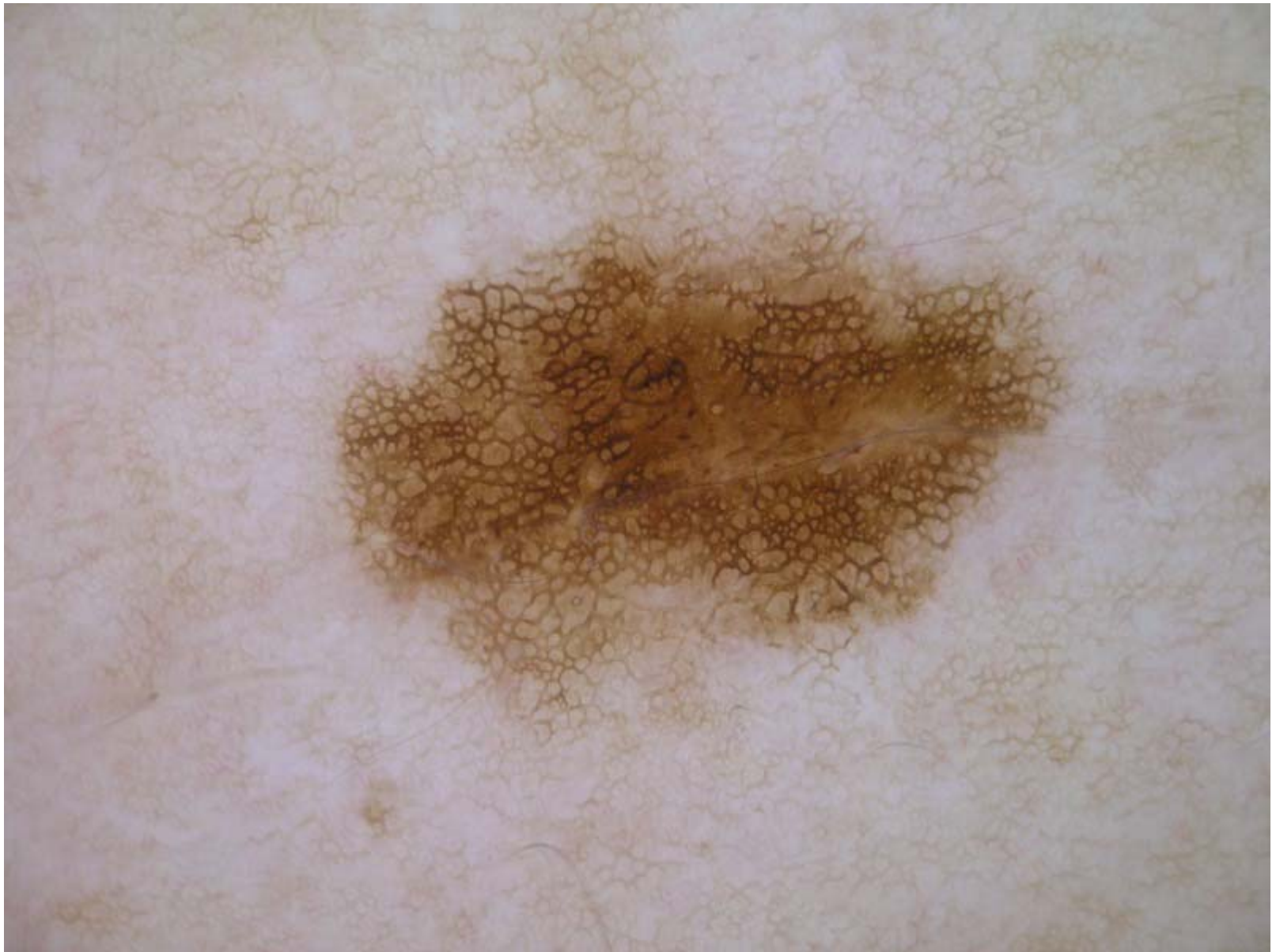






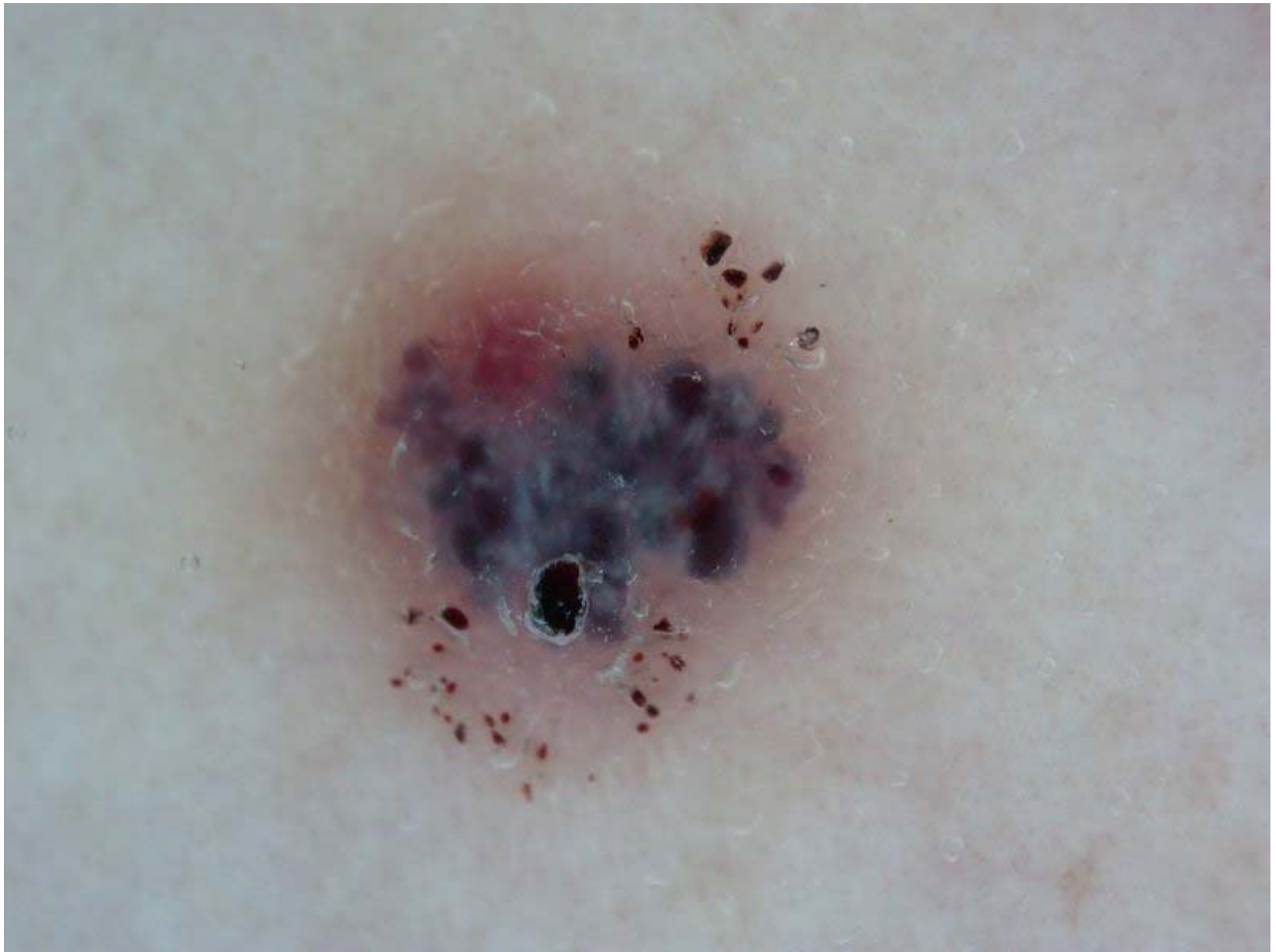





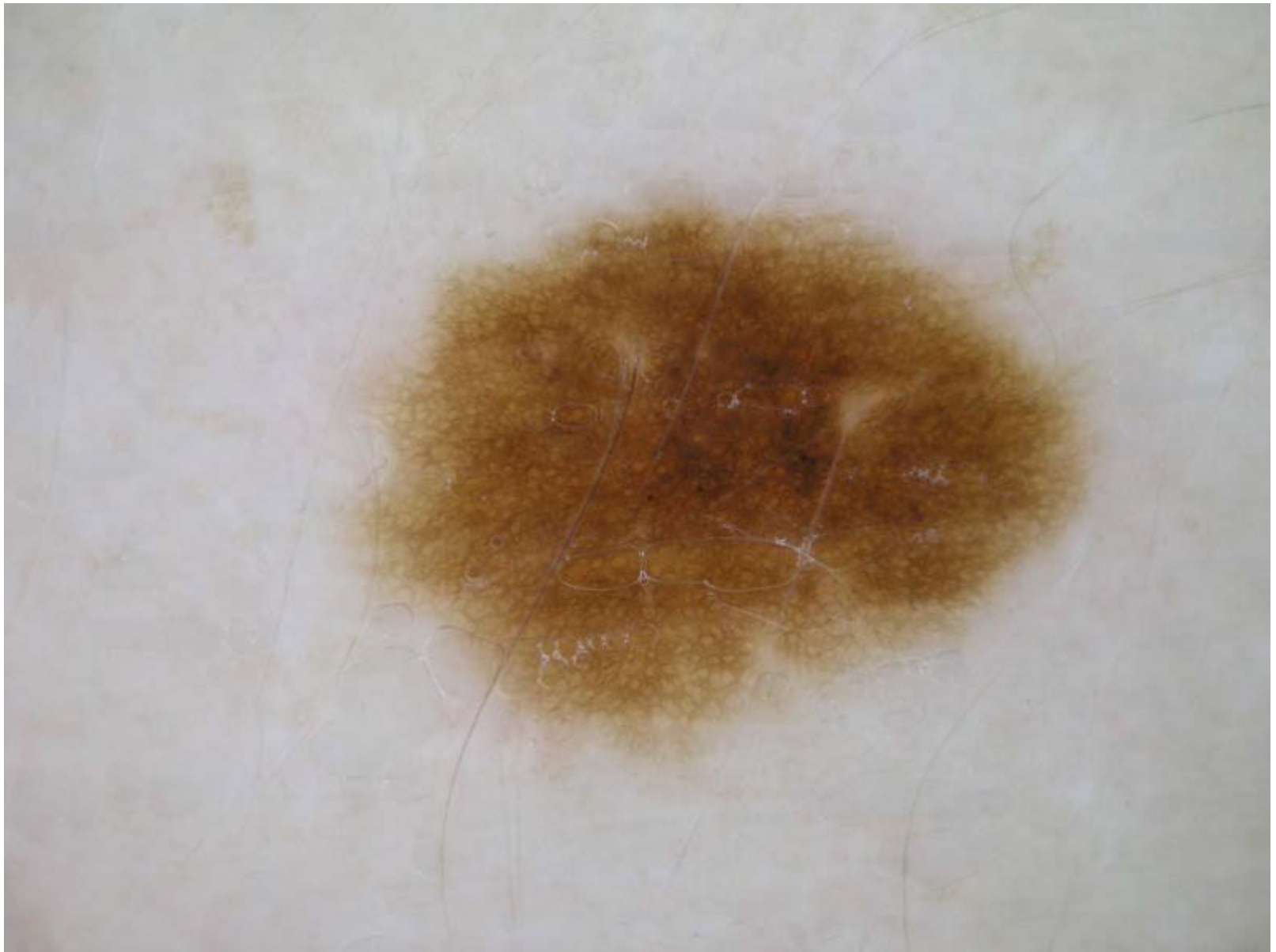










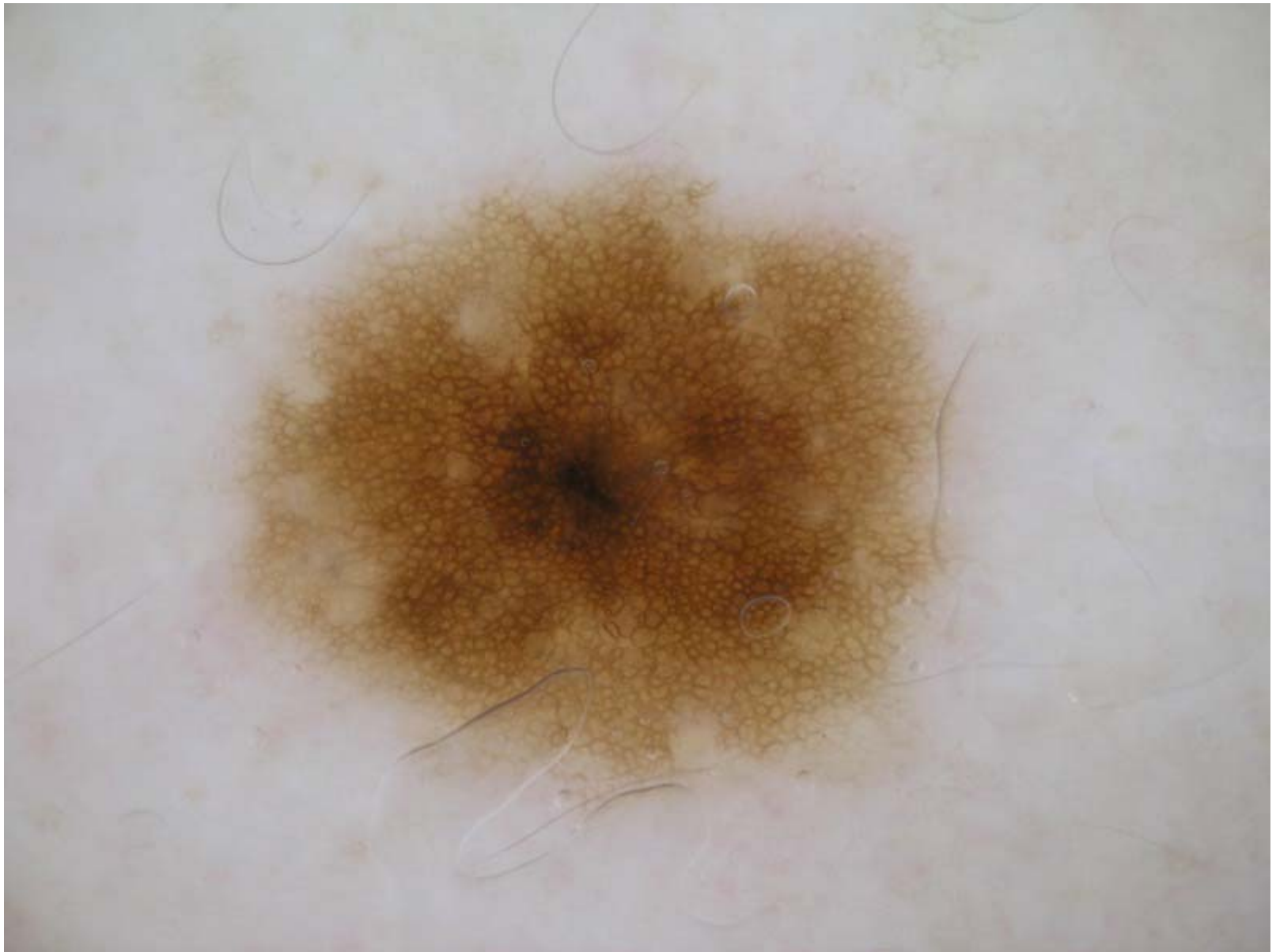


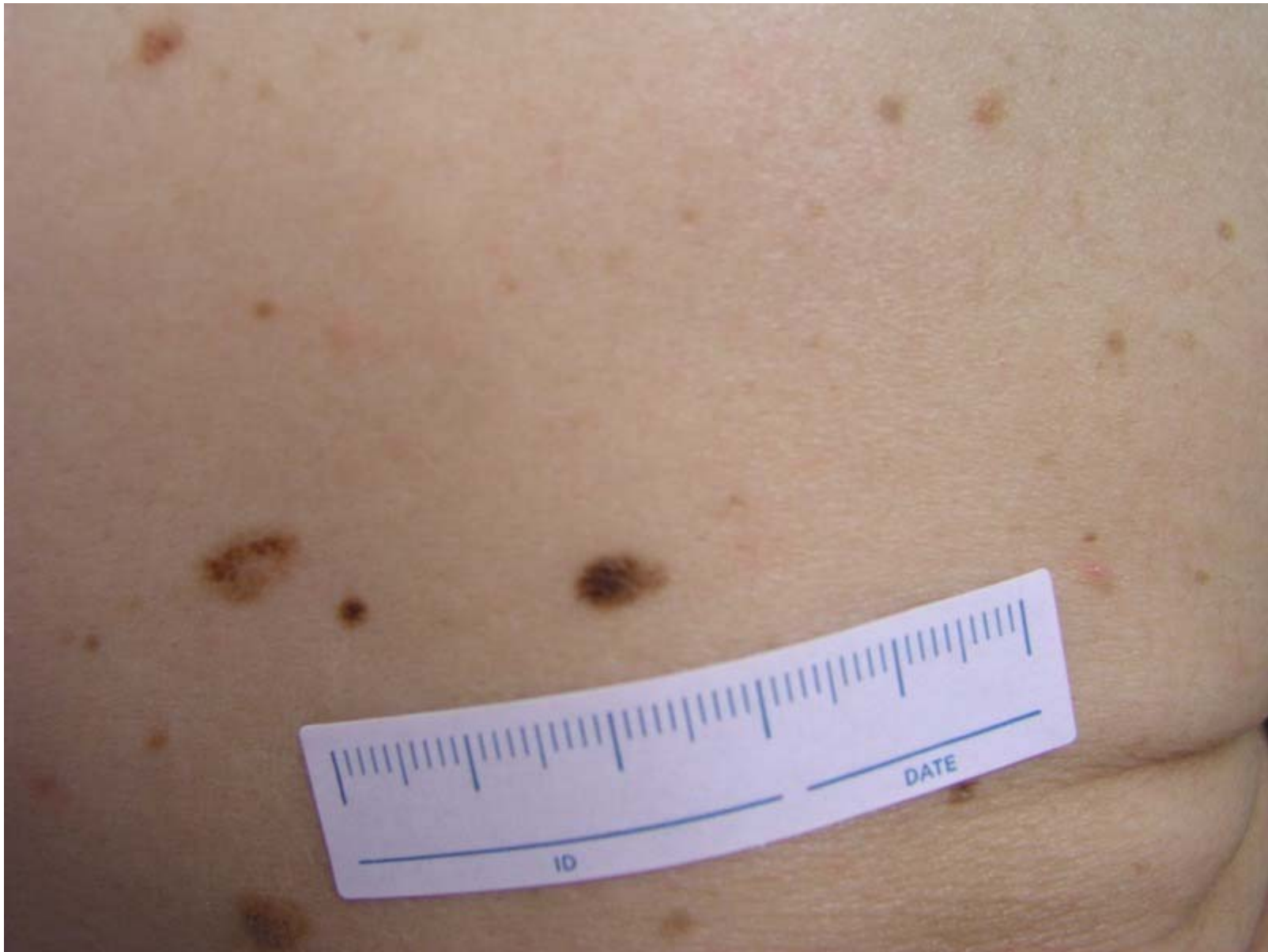


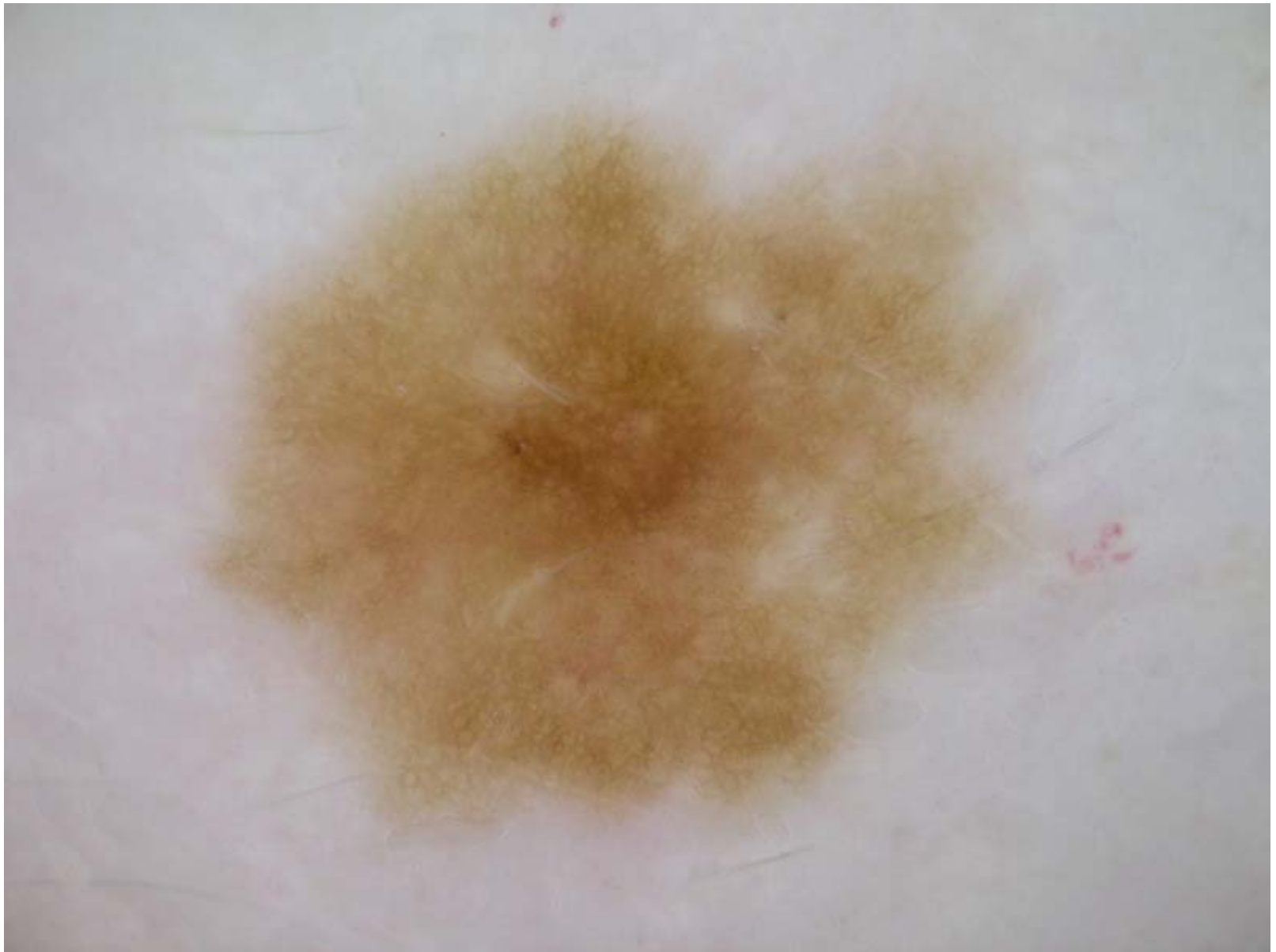


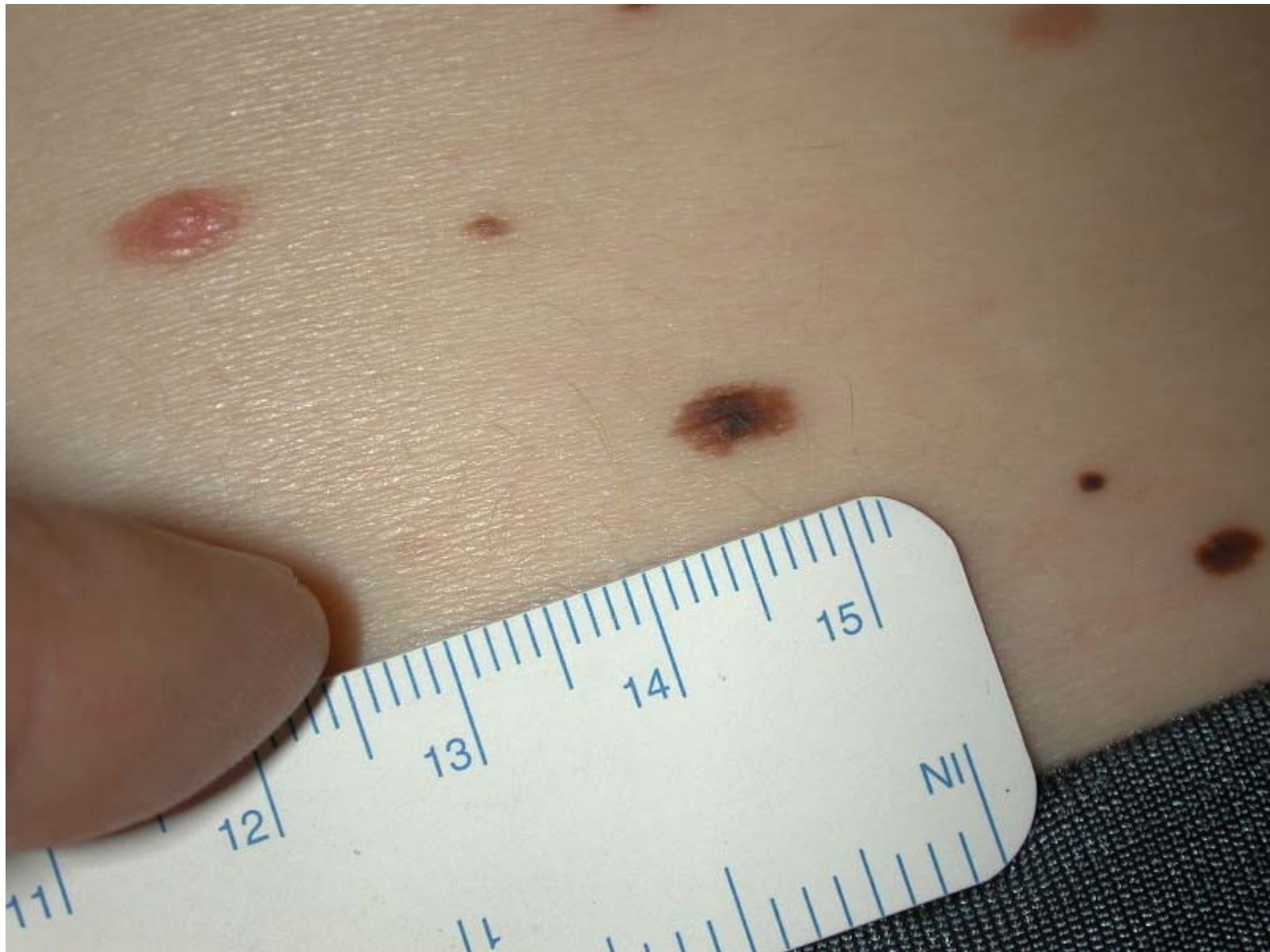


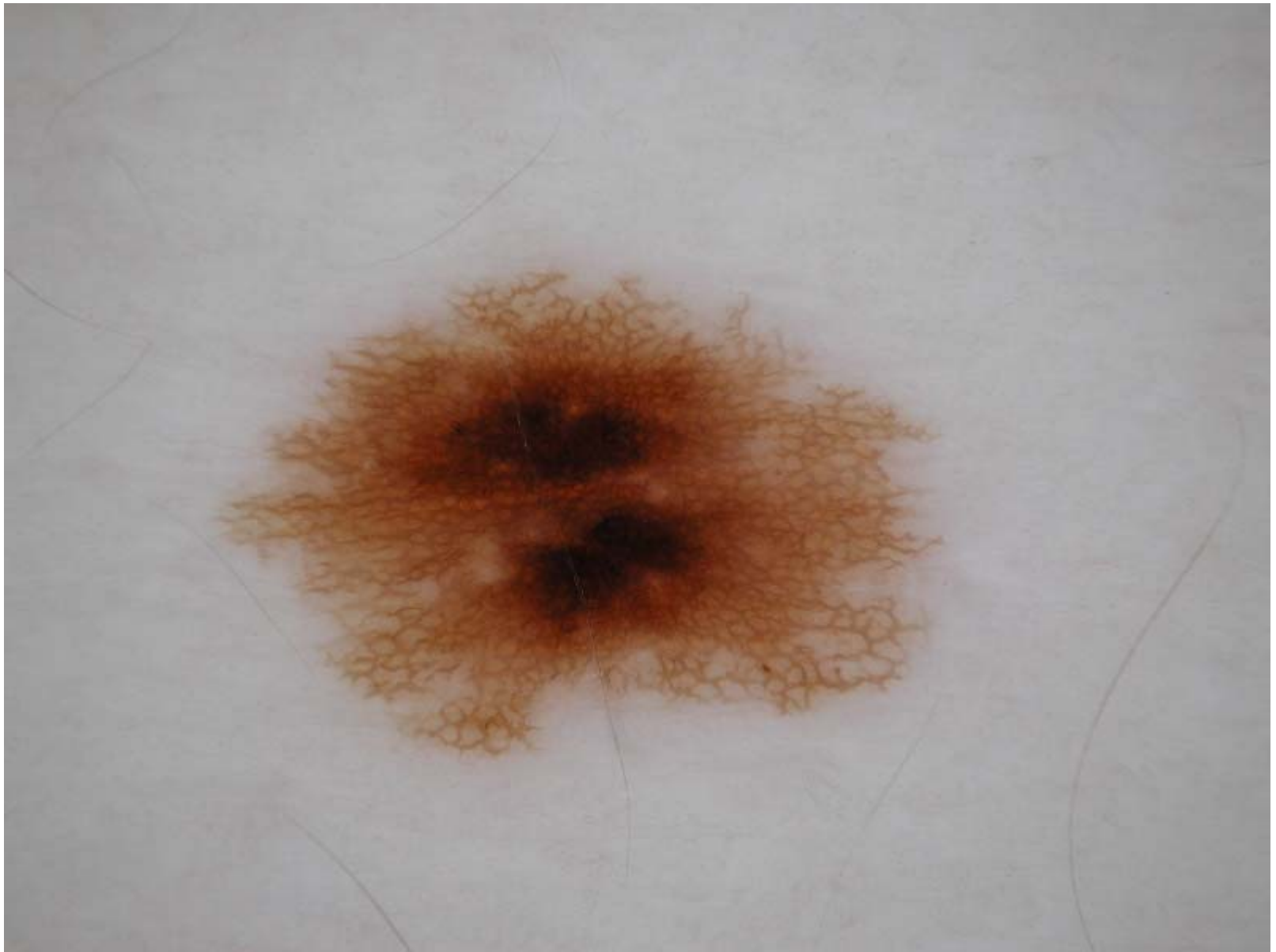

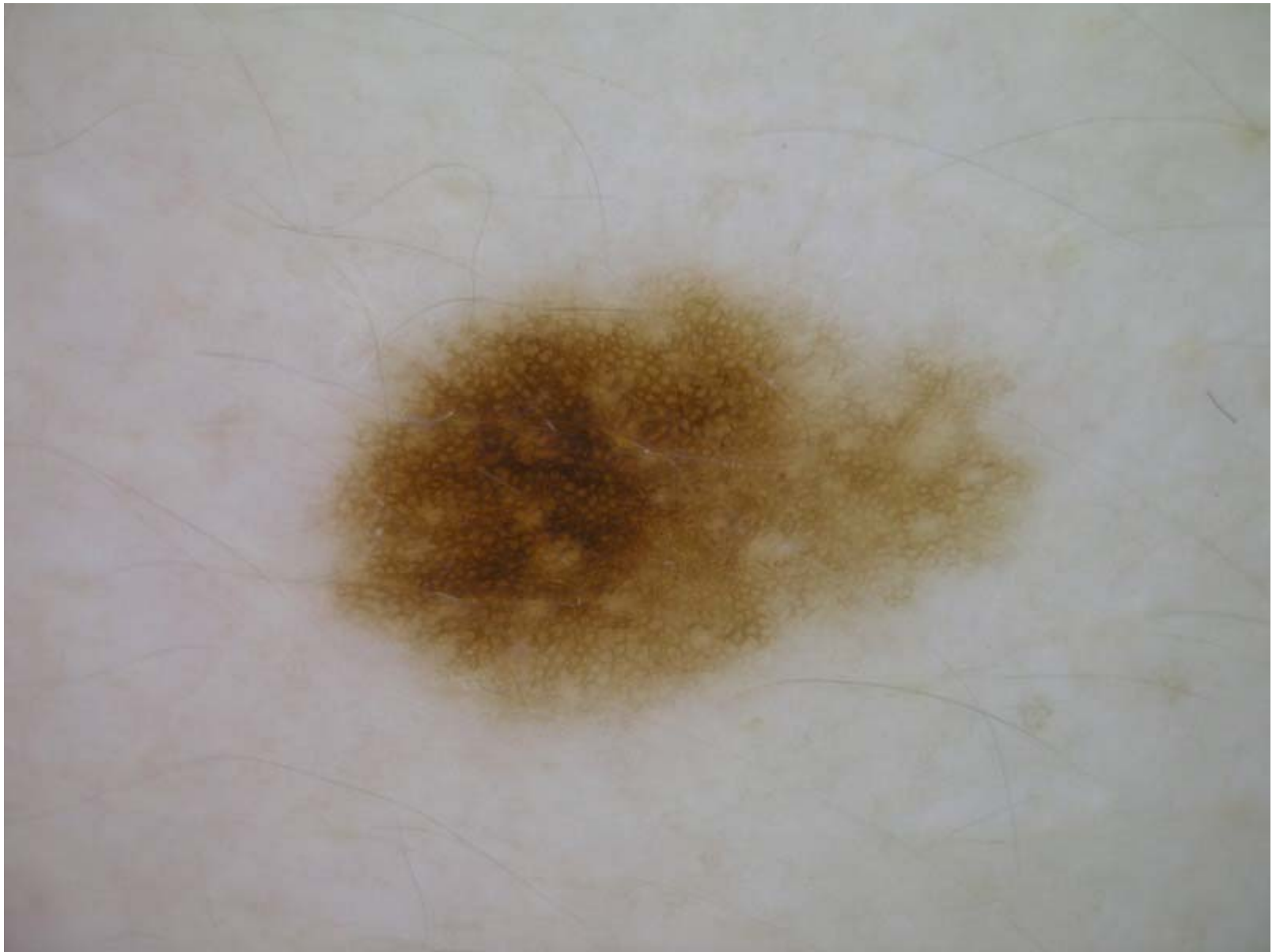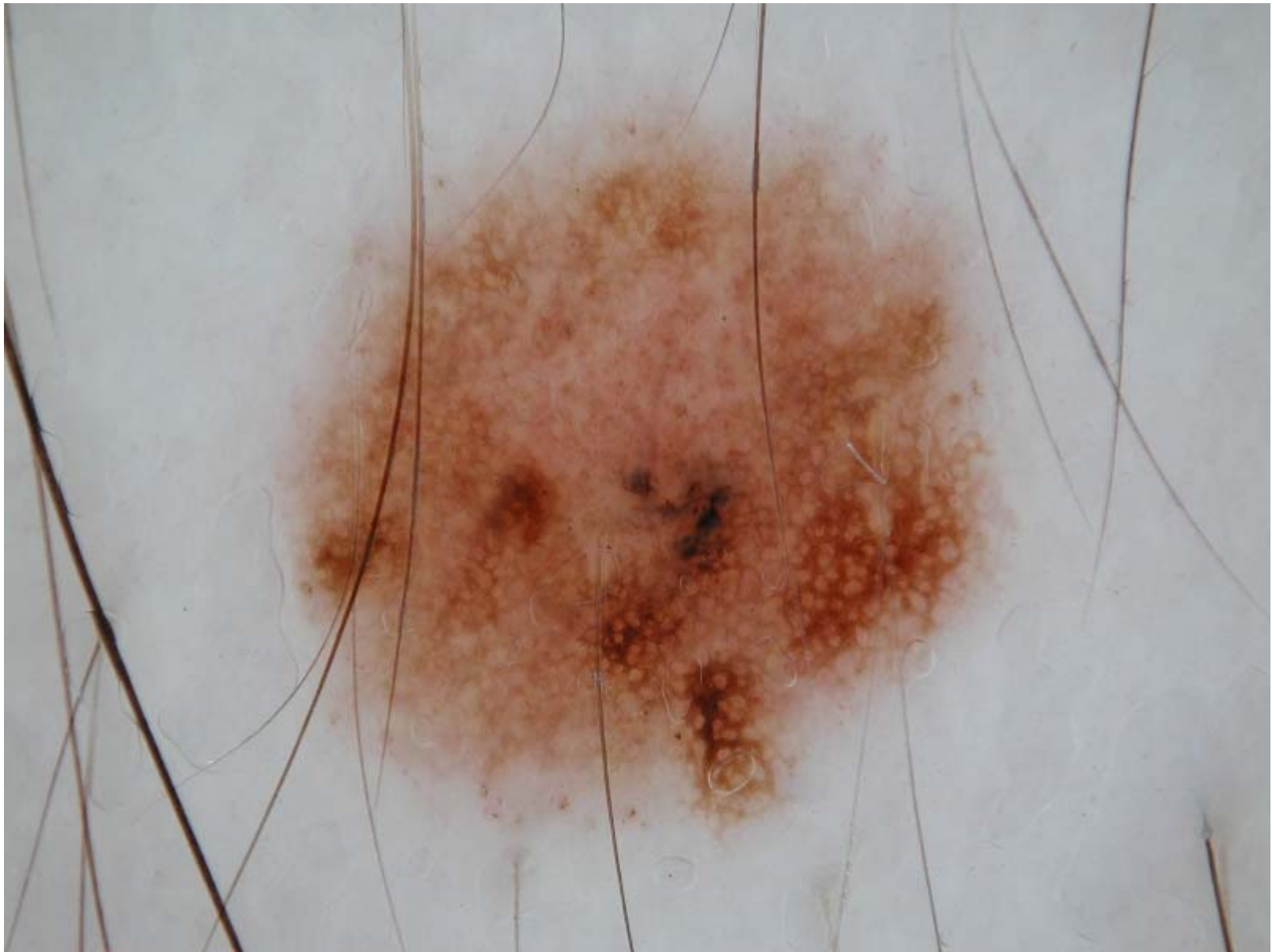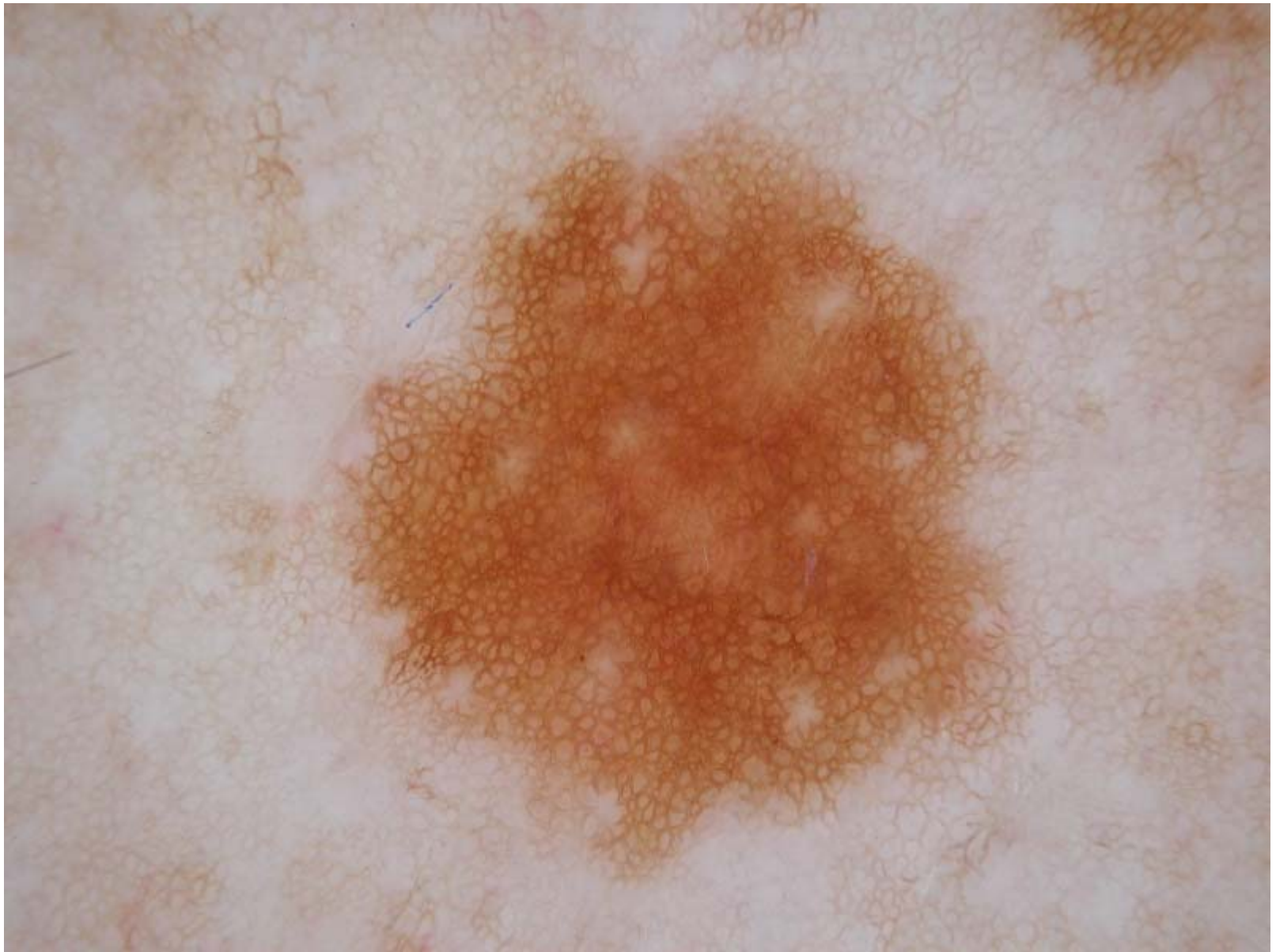








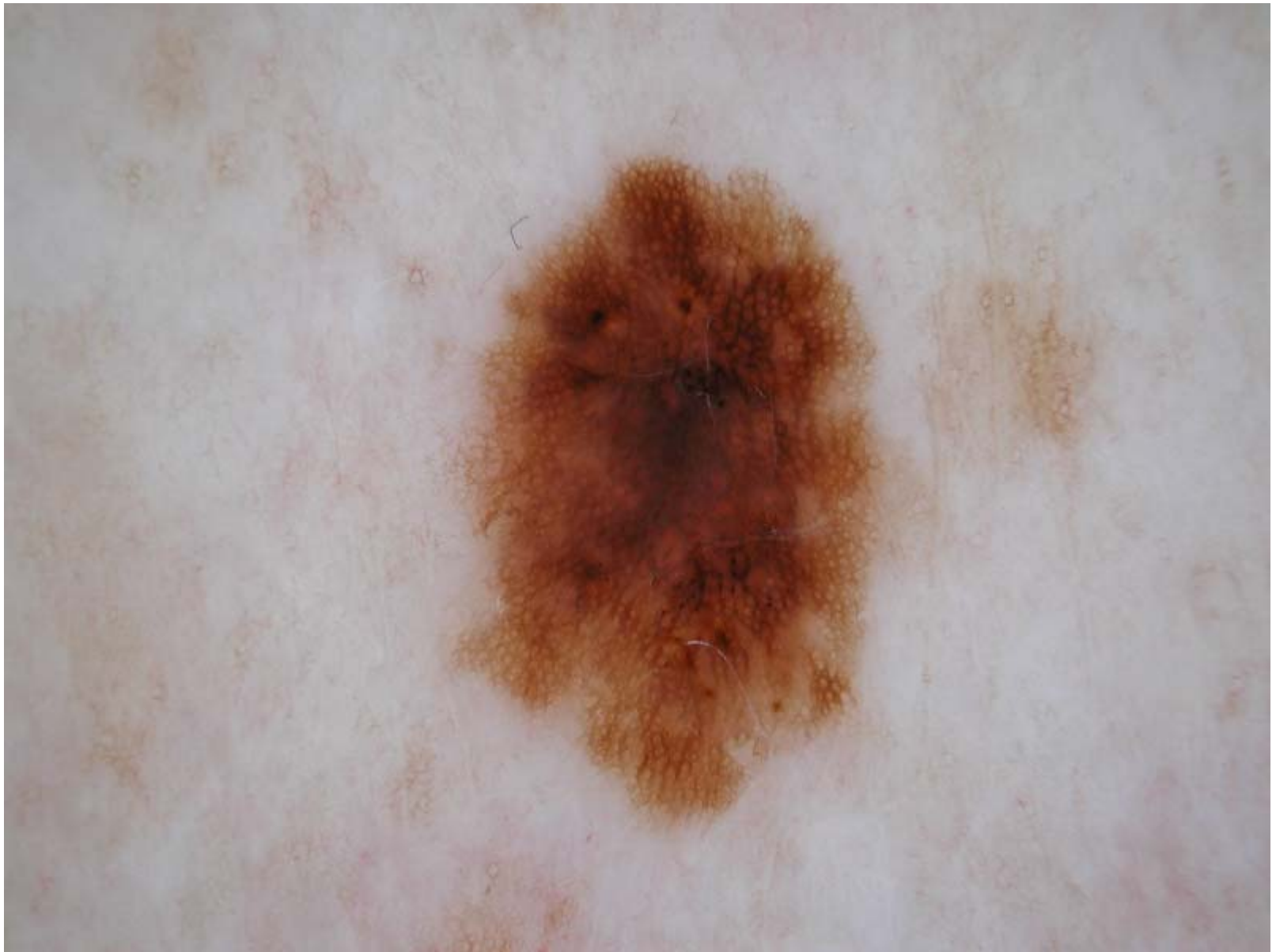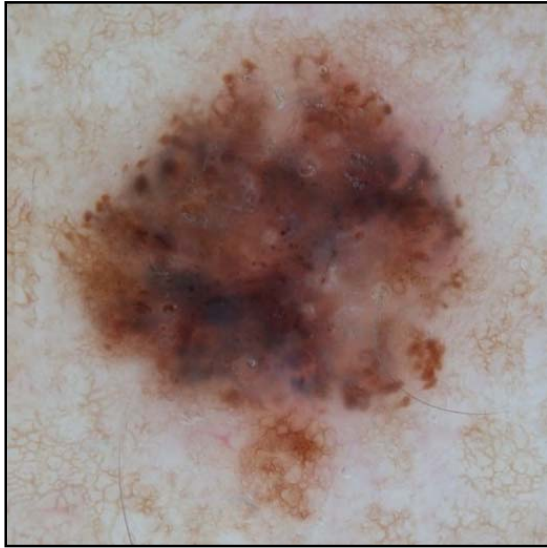








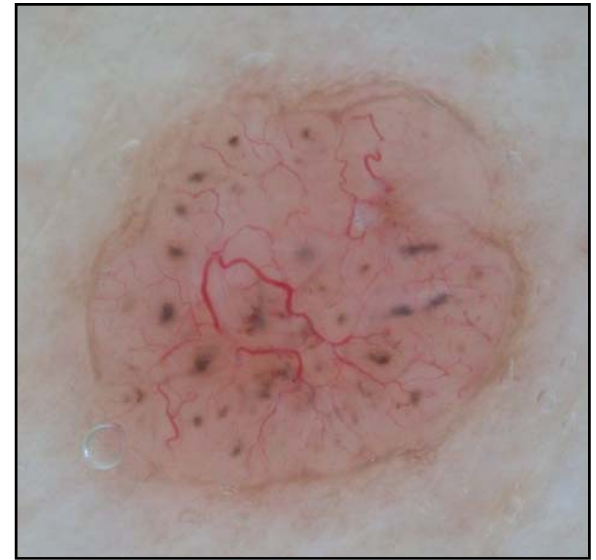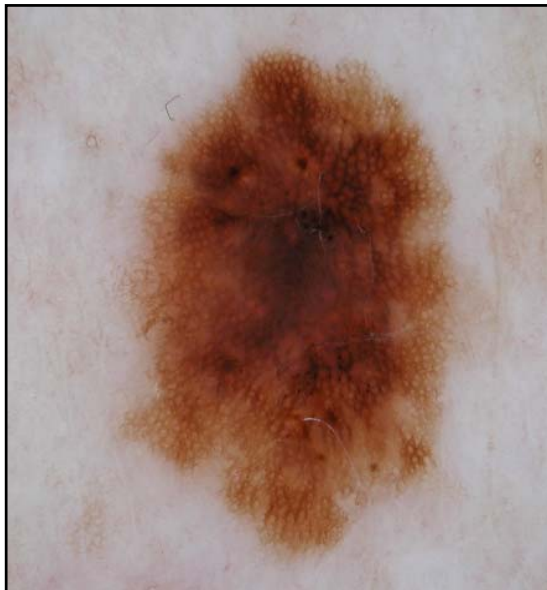At least these lesions should be removed:



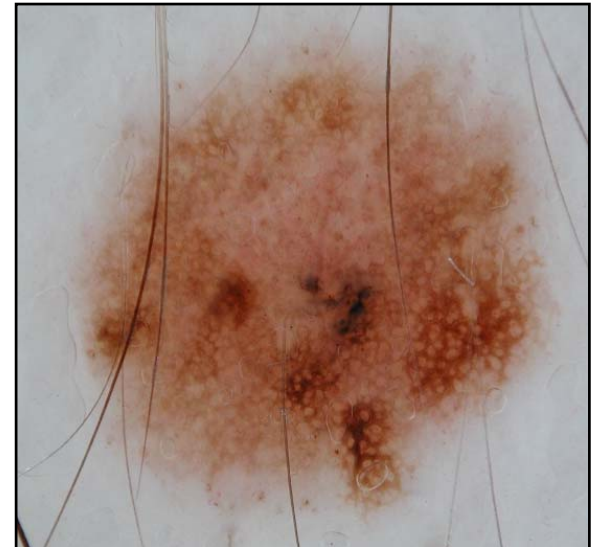Case 3
Melanoma



Case 4
BCC



Case 15
Atypical nevus



Case 13
Atypical nevus