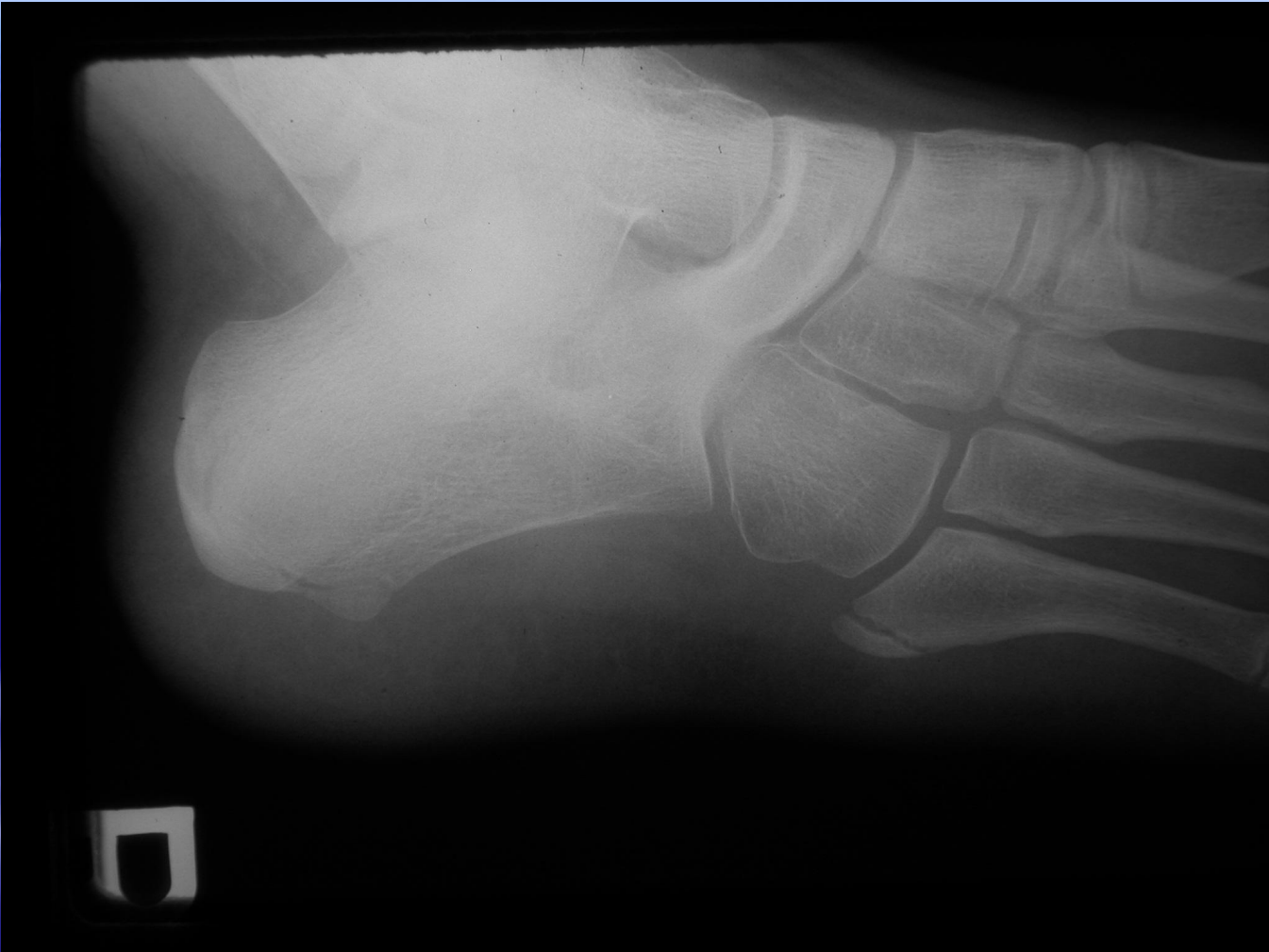
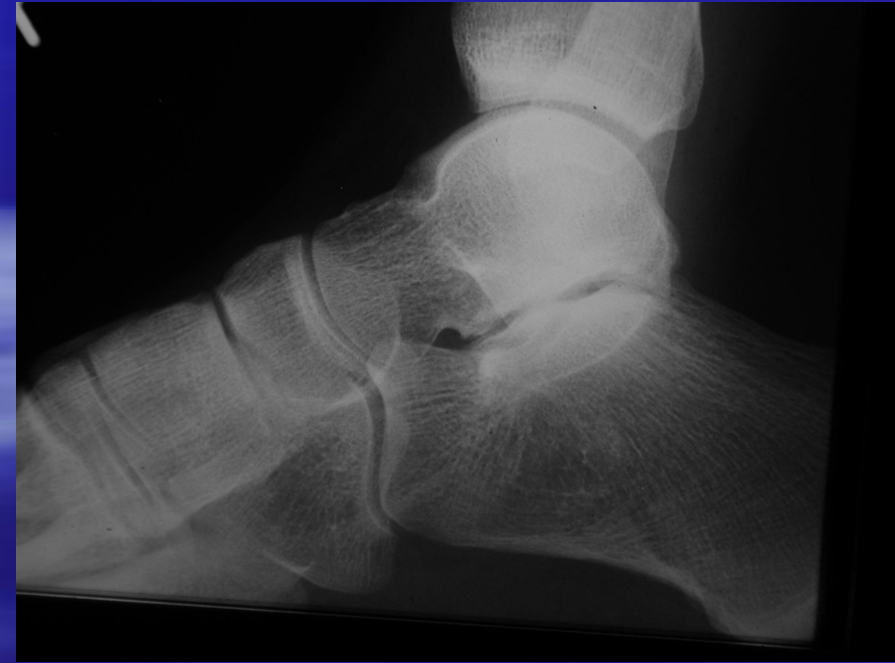
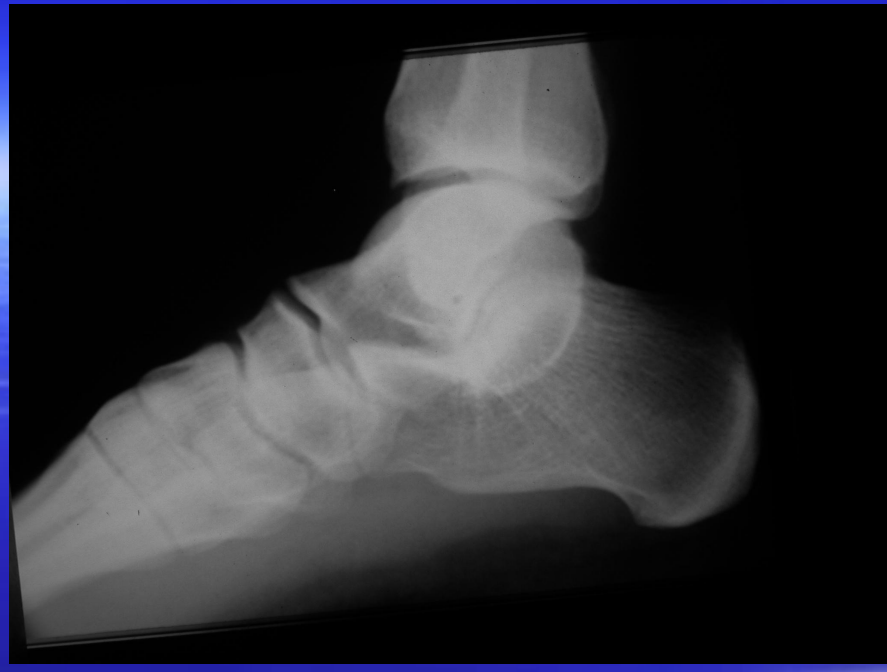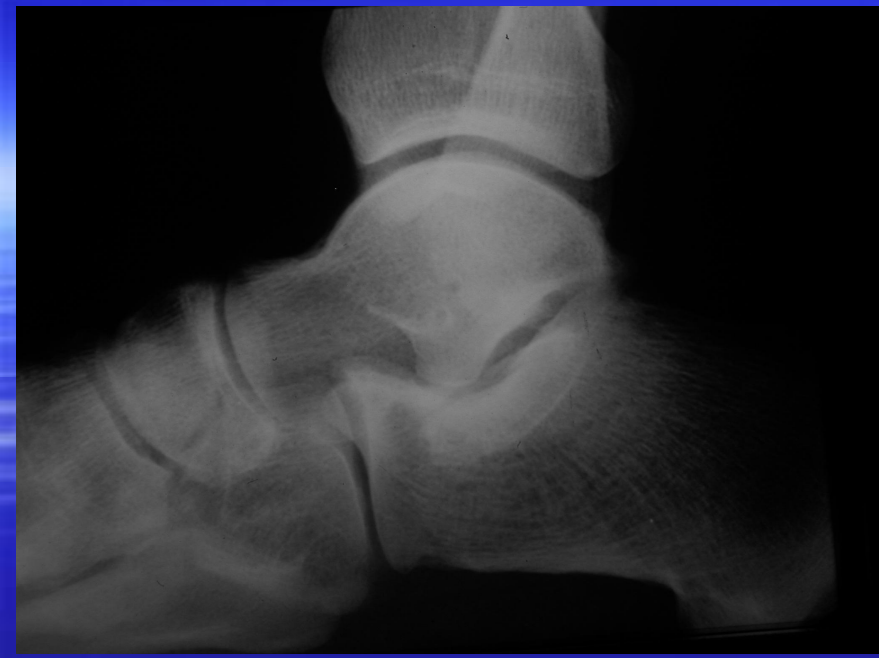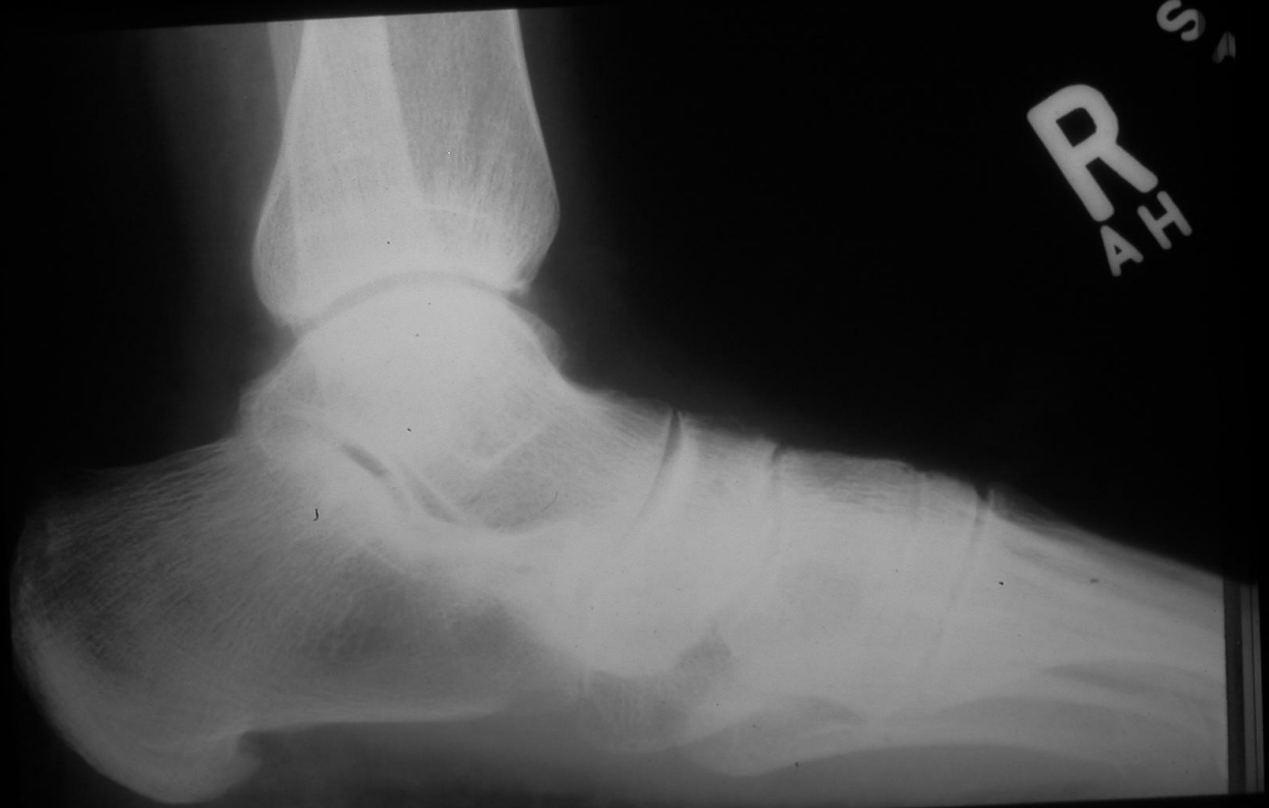FLEET

FLEET

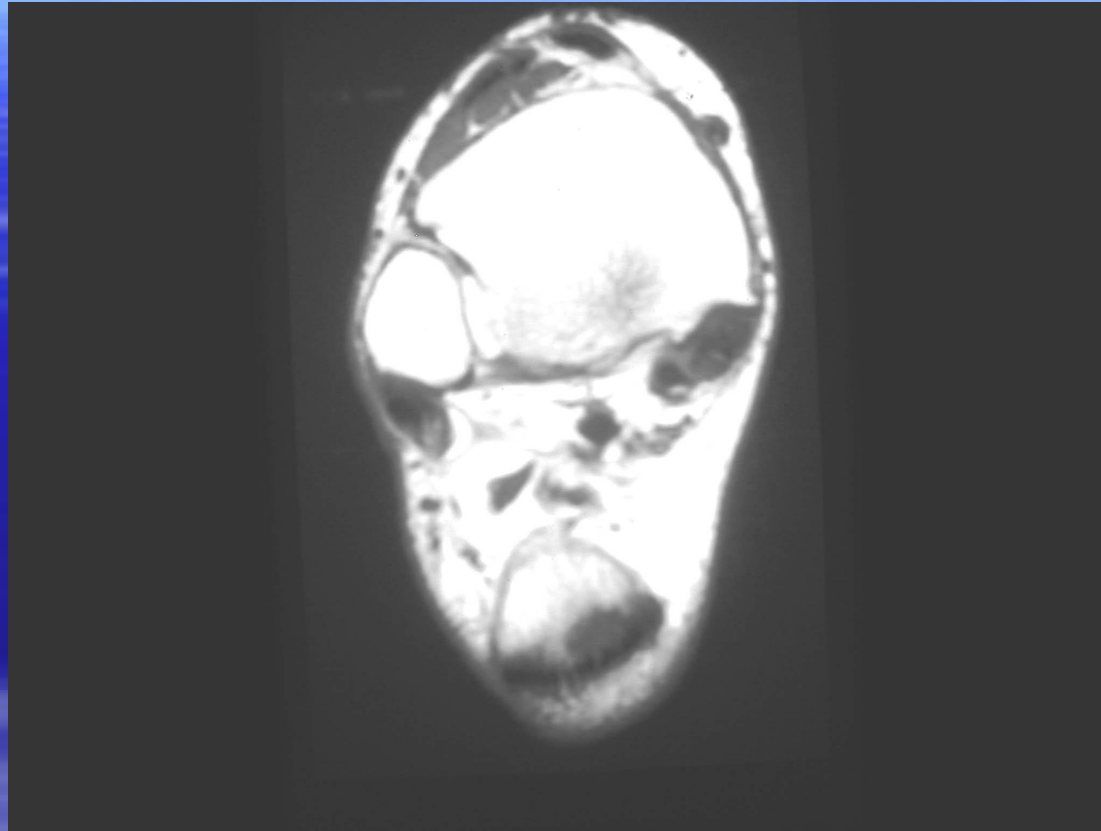




is one of the most common
osteolytic lesions of the
distal femur and is often
seen in the intercondylar notch



R
A
H
S



Tibialis posterior

QuickTime™ and a
decompressor
are needed to see this picture.

QuickTime™ and a
decompressor
are needed to see this picture.



QuickTime™ and a
decompressor
are needed to see this picture.

QuickTime™ and a
decompressor
are needed to see this picture.

QuickTime™ and a
decompressor
are needed to see this picture.

Coronal US Lisfranc Injury

QuickTime™ and a
decompressor
are needed to see this picture.

Jacques Lisfranc (1790-1847)

QuickTime™ and a
decompressor
are needed to see this picture.

QuickTime™ and a
decompressor
are needed to see this picture.

QuickTime™ and a
decompressor
are needed to see this picture.

QuickTime™ and a
decompressor
are needed to see this picture.